Indexed
PubMed and
PubMed Central
included
ISI and JCR (Journal Citation Reports®)

ISSN 1413-7852

Acta Ortopédica Brasileira

29 anos

Volume 29 – Number 4 – Year 2021

ISSN 1413-7852

Acta Ortopédica Brasileira

Department of Orthopedics and Traumatology, Faculdade de Medicina da Universidade de São Paulo (DOT/FMUSP), São Paulo, SP, Brazil

Affiliated with Associação Brasileira de Editores Científicos

Indexed in PubMed, PubMed Central, Web of Science, JCR, Scopus Elsevier, SciELO, Redalyc (Red de Revistas Cientificas de America Latina y el Caribe,España y Portugal), LILACS (Latin America Health Science Literature) and DOAJ (Directory of open access journals).

Editorial coordination, creation, desktop publishing and graphic production Atha Comunicação e Editora - e-mail: 1atha@uol.com.br

ACTA ORTOPÉDICA BRASILEIRA

INSTRUCTIONS TO AUTHORS

(Reviewed March 2021)

Scope and policy

The journal *Acta Ortopédica Brasileira*, official organ of the Department of Orthopedics and Traumatology, Faculdade de Medicina da Universidade de São Paulo (DOT/FMUSP), is published bimonthly in six issues per year (Jan/Feb, Mar/Apr, May/Jun, Jul/ Aug, Sep/Oct, and Nov/Dec) with English version. The titles, abstracts and keywords are published in English and Portuguese.The publication follows entirely the international standard of the International Committee of Medical Journal Editors (ICMJE) - Vancouver Convention - and its uniform requirements [http://www.icmje.org/]. Submitted papers are sent for peer review evaluation to decide whether they should be published or not, suggesting improvements, asking the authors for clarification and making recommendations to the Editor-in-Chief. The editor(s) and/or reviewer(s) responsible for approval of the manuscript will be identified in the accepted articles. The concepts and statements contained in the papers are the sole responsibility of the authors.

We ask authors to observe the following instructions for publication.

Publication Fee

To allow for the sustainability and continuity of the Acta Ortopédica Brasileira, we inform authors that starting in January 2017 a publication fee was instituted for articles. Authors are responsible for paying a fee to publish accepted articles, which will be charged to authors when their respective works are approved. Following the acceptance of the manuscript and notification by the editor-in-chief, authors should make a deposit in the name of the Atha Mais Editora LTDA, CNPJ14.575.980/0001-65, Santander (033) Bank agency 4337, account number 13001765-6. A copy of the deposit receipt should be sent to the email actaortopedicabrasileira@uol.com.br and include the work protocol number (AOB-0000), the article title, and the name of the article's author(s).

The fee is a R$ 1.150,00 (US$ 600). Upon submitting the manuscript and filling out the registration form, the author should read and agree to the terms of original authorship, relevance, and quality, as well as to the charging of the fee. Upon indicating agreement with these terms, the manuscript will be registered on the system for evaluation.

Recommendations for articles submitted to Acta Ortopédica Brasileira

Type of Article	Abstract	Number of words	References	Figures	Tables	Maximum number of authors allowed
Original	Structured, up to 200 words	2.500 Excluding abstract, references, tables and figures	20	10	6	6
Update / Review*	Non-structured, up to 200 words	4.000 Excluding abstract, references, tables and figures	60	3	2	2
Editorial*	No abstract	500	0	0	0	1

*These contributions shall be published at the Editors' criteria, with due replica, when applicable.

Article formatting

NUMBER OF WORDS RECOMMENDED ACCORDING TO THE PUBLICATION TYPE: The criteria specified below should be observed for each type of publication. The electronic counting of words should start at the Introduction and end at the Conclusion.

Manuscripts' form and presentation

MANUSCRIPT PREPARATION: The journal *Acta Ortopédica Brasileira* receives the following types of contributions: Original Article, Update Article and Review Article. The Update and Review articles are only considered by invitation from the Editorial Board. Manuscripts should be sent in .txt or .doc files, double-spaced, with wide margins. Articles should be submitted ideally in English and Portuguese. Measures should be expressed in the International System (*Système International*, SI), available at http://physics.nist.gov/cuu/Units and standard units, where applicable. It is recommended that authors do not use abbreviations in the title and limit their use in the abstract and in the text. This journal adopts Writecheck plagiarism detection system, however all published content are the sole responsibility of the authors. The generic names should be used for all drugs. The drugs can be referred to by their trade name, however, the manufacturer's name, city and country or electronic address should be stated in brackets in the Materials and Methods section

PRESENTATION LETTER: The cover letter accompanying the submission of the manuscript should be signed by the corresponding author and should include the following information: Title, names of all authors, text authorizing the publication of the article, stating that it has not being submitted simultaneously elsewhere and it has not been previously published (publication in another language is considered as the same article). Authors should make sure that the manuscript is entirely in accordance with the instructions.

PREPRINT: RBME accepts the submission of articles published as preprints. A preprint is a completed scientific manuscript that is deposited by the authors in a public server. It may have been previously published without having passed through a peer review and can be viewed free of charge by anyone in the world on platforms developed today for this purpose, such as the Scielo PrePrint platform (https://preprints.scielo.org/index.php/scielo/user/register). In most cases, a work published as a preprint is also submitted to a journal for peer review. Thus, preprints (not validated through peer review) and journal publications (validated through peer review) function in parallel as a communication system for scientific research.1,2

Data sharing: RBME encourages the sharing, citation and referencing of all data, program code and content underlying article texts in order to facilitate the evaluation of research, the reproducibility of studies, and the preservation and reuse of content. Data sharing can be published on the Scielo Dataverse platform, https://data.scielo.org/ Citations should facilitate access to research content and when articles, books, and online publications are cited, the data should be cited in an appropriate place in the text and the source included in the list of references in accordance with the Vancouver Style standards.3

ABBREVIATIONS: The use of abbreviations should be minimized. Abbreviations should be defined at the time of its first appearance in the abstract and also in the text. Non-standard abbreviations shall not be used, unless they appear at least three times in the text. Measurement units (3 ml or 3 mL, but not 3 milliliters) or standard scientific symbols (chemical elements, for example, Na, and not sodium) are not considered abbreviations and, therefore, should not be defined. Authors should abbreviate long names of chemical substances and therapeutic combinations terms. Abbreviations in figures and tables can be used for space reasons, but should be defined in the legend, even if they were defined in the article.

CLINICAL TRIALS: The journal *Acta Ortopédica Brasileira* supports the Clinical Trials Registry policy of the World Health Organization (WHO) and the ICMJE, recognizing the importance of these initiatives for the registration and international dissemination of clinical studies in open access. Therefore, it will only accept for publication articles involving clinical research that have received an identification number in one of the clinical trials registry platforms validated by WHO and ICMJE. The URLs of these registry platforms are available at the ICMJE page [http://www.icmje.org/about-icmje/faqs/clinical-trials-registration/].

CONFLICT OF INTERESTS: As recommended by the ICMJE and resolution of the Brazilian Federal Council of Medicine nº 1595/2000, authors have the responsibility to recognize and declare any potential financial conflicts of interest, as well as conflicts of other nature (commercial, personal, political, etc.) involved in developing the work submitted for publication.

CORRECTION OF PROOFS: As soon as they are ready, proofs in electronic format shall be sent via email to the author responsible for the article. Authors must return the proof with the appropriate corrections via email no later than 48 hours after having received them. The remittance and return of the proofs by electronic mail is intended to speed up the revision process and subsequent publication of these documents.

ELECTRONIC FILE ORGANIZATION: All parts of the manuscript must be included in a single file. This file must be organized to contain a cover page first, then the text and references followed by figures (with captions) and, at the end, tables and charts (with captions).

COVER PAGE: The cover page must contain:

a) type of article (original, revision or update article);

b) complete title in Portuguese and English with up to 80 characters, which must be concise yet informative;

c) The full name of each author (no abbreviations) and their affiliation (hierarchical units should be presented in ascending order, for example, department, college/institute and university. The names of institutions and programs should be submitted preferably in full and in the original language of the institution or in the English version when writing is not Latin (e.g. Arabic, Mandarin, Greek);

d)The place where the work was performed;

e)Name, address, telephone number and e-mail of the corresponding author.

ABSTRACT: The abstract in Portuguese and in English should be structured in cases of original articles and shall present the study's objectives clearly, methods, results and main conclusions and should not exceed 200 words (do not include any reference citations). Moreover, the abstract should include the level of evidence and the type of study, according to the classification table attached at the end of this text.

KEYWORDS: Must at least contain three keywords based on the Descritores de Ciências da Saúde (DeCS) - http://decs.bireme.br. In English, the keywords must be based on the Medical Subject Headings (MeSH) - http://www.nlm.nih.gov/mesh/meshhome.html, with at least three and at most, six citations.

INTRODUCTION: It must present the subject and the objective of the study, and provide citations without making any external review of the subject material.

ACKNOWLEDGEMENTS: Authors can acknowledge financial support to the work in the form of research grants, scholarships and other, as well as professionals who do not qualify as co-authors of the article, but somehow contributed to its development.

MATERIALS AND METHODS: This section should describe the experiments (quantitatively and qualitatively) and procedures in sufficient detail to allow other researchers to reproduce the results or provide continuity to the study. When reporting experiments on humans or animals, authors should indicate whether the procedures followed the rules of the Ethics Committee on Human Trials of the institution in which the survey was conducted, and whether the procedures are in accordance with the 1995 Helsinki Declaration and the Ethics in Experimentation Animals, respectively. Authors should include a statement indicating that the protocol was approved by the Institutional Ethics Committee (affiliate institution of at least one of the authors), with its identification number. It should also include whether a Free and Informed Consent Term was signed by all participants. Authors should precisely identify all drugs and chemicals used, including generic names, dosages and administration. Patients' names, initials, or hospital records should not be included. References regarding statistical procedures should be included.

RESULTS: Results should be present in logical sequence in the text, using tables and illustrations. Do not repeat in the text all the data in the tables and/or illustrations, but emphasize or summarize only the most relevant findings.

DISCUSSION: Emphasize new and important aspects of the study and the conclusions that derive from it, in the context of the best evidence available. Do not repeat in detail data or other information mentioned elsewhere in the manuscript, as in the Introduction or Results. For experimental studies it is recommended to start the discussion by briefly summarizing the main findings, then explore possible mechanisms or explanations for these findings, compare and contrast the results with other relevant studies, state the limitations of the study and explore the implications of these results for future research and for clinical practice. Link the conclusions with the goals of the study, but avoid statements and conclusions that are not supported by the data, in particular the distinction between clinical and statistical relevance. Avoid making statements on economic benefits and costs, unless the manuscript includes data and appropriate economic analysis. Avoid priority claim ("this is the first study of ...").

CONCLUSION: The conclusion should be clear and concise, establishing a link between the conclusion and the study objectives. Avoiding conclusions not based on data from the study in question is recommended, as well as avoiding suggest that studies with larger samples are needed to confirm the results of the work in question.

ACKNOWLEDGEMENTS

When applicable, briefly acknowledge the people who have contributed intellectually or technically to the study, but whose contribution does not justify authorship. The author must ensure that people agree to have their names and institutions disclosed. Financial support for the research and fellowships should be acknowledged in this section (funding agency and project number).

IDENTIFICATION OF THE AUTHORS: The ORCID number (Open Researcher and Contributor ID, http://orcid.org) of each of the authors, following the name of the respective author, and the complete link must be included on the cover page.

DECLARATION OF THE CONTRIBUTION OF THE AUTHORS: The declaration of the contribution of the authors must be included at the end of the article using at least two criteria of authorship, among them:

Substantial contribution to the concept or design of the work, or acquisition, analysis, or interpretation of the study data;

Writing of the work or critical review of its intellectual content;

Final approval of the version of the manuscript to be published.

All the authors must be included in the declaration, according to the model:

"Each author made significant individual contributions to the development of this manuscript. Faloppa F: writing and performing surgeries; Takimoto ES: data analysis and performing surgeries; Tamaoki MJS: review of the article and intellectual concept of the article."

REFERENCES: References: Cite up to about 20 references, restricted to the bibliography essential for the article's content. Number references consecutively, as they first appear in the text, using superscripted Arabic numerals in the following format: (Reduction of functions of the terminal plate.1) Please include the first six authors followed by et al. Journal names must be abbreviated according to the Index Medicus.

a) Articles: Author(s). Article title. Journal title. year; volume: initial page – final page

Ex.: Campbell CJ. The healing of cartilage defects. Clin Orthop Relat Res. 1969;(64):45-63.

b) Books: Author(s) or publisher(s). Book title. Edition, if other than the first one. Translator (s), if applicable. Publication site: publisher; year. Ex.: Diener HC, Wilkinson M, editors. Drug-induced headache. 2nd ed. New York: Spriger-Verlag; 1996.

c) Book chapters: Author(s) of the chapter. Chapter heading. Publisher (s) of the book and other related data according to previous item. Ex.: Chapman MW, Olson SA. Open fractures. In: Rockwood CA, Green DP. Fractures in adults. 4th ed. Philadelphia: Lippincott-Raven; 1996. p.305-52.

d) Summaries: Author(s). Title, followed by [abstract]. Journal year; volume (supplement and corresponding number, if applicable): page(s) Ex.: Enzensberger W, Fisher PA. Metronome in Parkinson's disease [abstract]. Lancet. 1996;34:1337.

e) Personal communications must only be mentioned in the text if within parentheses

f) Thesis: Author, title (master, PhD etc.), city: institution; year. Ex.: Kaplan SJ. Post-hospital home health care: the elderly's access and utilization [dissertation]. St. Louis: Washington Univ.; 1995.

g) Electronic material: Author (s). Article title. Abbreviated Journal title [medium]. Publication date [access date followed by the expression "accessed on"]; volume (number):initial page-final page or [approximate number of pages]. URL followed by the expression "Available from:"

Ex.: Pavezi N, Flores D, Perez CB. Proposição de um conjunto de metadados para descrição de arquivos fotográficos considerando a Nobrade e a Sepiades. Transinf. [Internet]. 2009 [acesso em 2010

nov 8];21(3):197-205. Available from: http://periodicos.puc-campinas.edu.br/seer/index.php/transinfo/article/view/501

h) Data Sharing: Pavezi N, Flores D, Perez CB. Proposição de um conjunto de metadados para descrição de arquivos fotográficos considerando a Nobrade e a Sepiades. Transinf. [Internet]. 2009. Available at: https://doi.org/10.1590/S0103-37862009000300003. Write [dataset] immediately before the reference so we can identify it properly as a data reference. The identifier [dataset] will not appear in the published article.

TABLES: Tables should be numbered in order of appearance in the text with Arabic numerals. Each table should have a title and, when necessary, an explanatory caption. Charts and tables should be sent in editable source files (Word, Excel) and not as images. Tables and charts covering more than one page should be avoided. Do not use image elements, text boxes, or tabs.

FIGURES (ILLUSTRATIONS AND PHOTOS): Figures should be submitted on separate pages and numbered sequentially in Arabic numerals, according to the order of appearance in the text. To avoid issues that compromise the journal pattern, all material sent shall comply with the following parameters: all graphics, photographs and illustrations should have adequate graphic quality (300 dpi resolution) and present title and caption. In all cases, the files must have .tif or .jpg extensions. Files with extension .xls, .xlsx (Excel), .eps or .psd to curve illustrations (graphics, drawings and diagrams) shall also be accepted. Figures include all illustrations such as photographs, drawings, maps, graphs, etc. Black and white figures will be freely reproduced, but the editor reserves the right to set a reasonable limit on their number or charge the author the expense resulting from excesses. Color photos will be charged to the author.

Please note that it is the authors' responsibility to obtain permission from the copyright holder to reproduce figures (or tables) that have been previously published elsewhere. Authors must have permission from the copyright owner, if they wish to include images that have been published in other non-open access journals. Permission shall be indicated in the figure legend, and the original source must be included in the reference list.

LEGENDS TO FIGURES: Type the legends using double space, following the respective figures (graphics, photos and illustrations). Each legend must be numbered in Arabic numerals corresponding to each illustration and in the order they are mentioned in the text. Abbreviations and acronyms should be preceded by the full name when cited for the first time in the text. At the bottom of figures and tables discriminate the meaning of abbreviations, symbols, signs and other informed source. If the illustrations have already been published, they shall be accompanied by written consent of the author or editor, stating the reference source where it was originally published.

PAPER SUBMISSION: From January 2008 *Acta Ortopédica Brasileira* adopts the SciELO Publication and Submission System available online at http://submission.scielo.br/index.php/aob/index. Authors should follow the registration and article inclusion instructions available at the website.

LEVELS OF EVIDENCE FOR PRIMARY RESEARCH QUESTION: Access the following link.

The sending of manuscripts

PAPER SUBMISSION: From January 2008 *Acta Ortopédica Brasileira* adopts the SciELO Publication and Submission System available online at http://submission.scielo.br/index.php/aob/index. Authors should follow the registration and article inclusion instructions available at the website

The authors are solely responsible for the concepts presented in the articles.

If you require additional clarifications, please contact Atha Comunicação e Editora - Rua: Machado Bittencourt, 190, 4º andar - Vila Mariana - São Paulo, SP, CEP 04044-000 - Email: actaortopedicabrasileira@uol.com.br – phone number 55-11-5087-9502 and speak to Ana Carolina de Assis/Arthur T. Assis.

Sources:
http://blog.scielo.org/blog/ 2017/02/22/scielo-preprints-a-caminho/#.Wt3U2IjwY2w
http://asapbio.org/preprint-info
https://blog.scielo.org/blog/2020/05/13/scielo-atualiza-os-criterios-de-indexacao-nova-versao-vigora-a-partir-de-maio-de-2020/

For further information please contact Atha Comunicação e Editora. Rua Machado Bittencourt 190, 4° floor. Vila Mariana, 04044-000. São Paulo, SP, Brazil. actaortopedicabrasileira@uol.com.br. Tel. +55 11 5087-9502 c/o Ana Carolina de Assis/Arthur T. Assis.

Levels of Evidence for Primary Research Question[a]

(This chart was adapted from material published by the Centre for Evidence-Based Medicine, Oxford, UK. For more information, please visit www.cebm.net.)

	Types of study			
Level	**Therapeutic Studies Investigating the Results of Treatment**	**Prognostic Studies – Investigating the Effect of a Patient Characteristic on the Outcome of Disease**	**Diagnostic Studies – Investigating a Diagnostic Test**	**Economic and Decision Analyses – Developing an Economic or Decision Model**
I	High quality randomized trial with statistically significant difference or no statistically significant difference but narrow confidence intervals	High quality prospective study[d] (all patients were enrolled at the same point in their disease with ≥80% of enrolled patients)	Testing of previously developed diagnostic criteria on consecutive patients (with universally applied reference "gold" standard)	Sensible costs and alternatives; values obtained from many studies; with multiway sensitivity analyses
	Systematic review[b] of Level RCTs (and study results were homogenous[c])	Systematic review[b] of Level I studies	Systematic review[b] of Level I studies	Systematic review[b] of Level I studies
II	Lesser quality RCT (eg, < 80% followup, no blinding, or improper randomization)	Retrospective[f] study	Development of diagnostic criteria on consecutive patients (with universally applied reference "gold" standard)	Sensible costs and alternatives; values obtained from limited studies; with multiway sensitivity analyses
	Prospective[d] comparative study[e]	Untreated controls from an RCT	Systematic review[b] of Level II studies	Systematic review[b] of Level II studies
	Systematic review[b] of Level II studies or Level I studies with inconsis tent results	Lesser quality prospective study (eg, patients enrolled at different points in their disease or <80% followup)		
		Systematic review[b] of Level II studies		
III	Case control study[g]	Case control study[g]	Study of non consecutive patients; without consistently applied reference "gold" standard	Analyses based on limited alternatives and costs; and poor estimates
	Retrospective[f] comparative study[e]		Systematic review[b] of Level III studies	Systematic review[b] of Level III studies
	Systematic review[b] of Level III studies		Case-control study	
			Poor reference standard	
IV	Case series[h]	Case series		Analyses with no sensitivity analyses
V	Expert opinion	Expert opinion	Expert opinion	Expert opinion

[a] A complete assessment of quality of individual studies requires critical appraisal of all aspects of the study design.
[b] A combination of results from two or more prior studies.
[c] Studies provided consistent results.
[d] Study was started before the first patient enrolled.
[e] Patients treated one way (eg, cemented hip arthroplasty) compared with a group of patients treated in another way (eg, uncemented hip arthroplasty) at the same institution.
[f] The study was started after the first patient enrolled.
[g] Patients identified for the study based on their outcome, called "cases" eg, failed total arthroplasty, are compared with patients who did not have outcome, called "controls" eg, successful total hip arthroplasty.
[h] Patients treated one way with no comparison group of patients treated in another way.

VOLUME 29 – Nº 4 – 2021

Original Article

DOI: http://dx.doi.org/10.1590/1413-785220212904240893

SUBTALAR JOINT IN NEUTRAL AND RELAXED POSITIONS FOR EVALUATION OF MEDIAL LONGITUDINAL ARCH

ARTICULAÇÃO SUBTALAR EM POSIÇÕES NEUTRA E RELAXADA PARA AVALIAÇÃO DO ARCO LONGITUDINAL MEDIAL

André Setti Persiane[1,2], Daiane Magalhães Gomes Negrão[1], Raone Daltro Paraguassu Alves[1], Diego Galace de Freitas[1,2], Cláudio Cazarini Júnior[1,2], Vera Lúcia dos Santos Alves[1]

1. Faculdade de Ciências Médicas da Santa Casa de São Paulo, São Paulo, SP, Brazil.
2. Universidade Paulista (UNIP), São Paulo, SP, Brazil.

ABSTRACT

Objective: The medial longitudinal arch is the main structure of load bearing and shock absorption of the foot. The evaluation of medial longitudinal arch, such as the navicular height, the medial longitudinal arch angle and the Feiss line should be performed with the subtalar joint in the neutral and relaxed position. Our study analyzed the correlation between the measurements of the subtalar joint in neutral and relaxed positions during the evaluation tests of the medial longitudinal arch. Methods: This is a cross-sectional study, in which 51 healthy volunteers (102 feet; 36 women; 28 ± 5 years, 1.66 ± 0.10 m; 24.5 ± 4.5 kg/m2) had their navicular height, medial longitudinal arch angle and Feiss line measured in the neutral and relaxed positions. The correlation between the measures was evaluated using Pearson's test. Results: A strong correlation of the 102 feet Feiss line measurements between neutral and relaxed positions (r = 0.81) was observed, and a moderate correlation between the medial longitudinal arch angle (r = 0.78) and between navicular height in neutral and relaxed positions (r = 0.76). Conclusion: The measurements of the longitudinal medial arch between the neutral and relaxed positions are strongly correlated. Therefore, it is not necessary to measure the medial longitudinal arch in both neutral and relaxed positions. ***Level of Evidence II, Diagnostic Studies – Investigating a diagnostic test.***

Keywords: Ankle. Flatfoot. Foot. Foot Deformities. Talipes Cavus. Tarsal Bones.

RESUMO

Objetivo: O arco longitudinal medial é a estrutura principal para suporte de carga e absorção de impacto no pé. Medidas para avaliação do arco longitudinal medial, como a altura navicular, o ângulo do arco longitudinal medial e a linha de Feiss devem ser realizadas com a articulação subtalar na posição neutra e relaxada. Este estudo analisou a correlação entre as medidas da articulação subtalar em posições neutra e relaxada durante os testes de avaliação do arco longitudinal medial. Métodos: Neste estudo transversal, 51 voluntários saudáveis (102 pés; 36 mulheres; 28 ± 5 anos, 1,66 ± 0,10 m; 24,5 ± 4,5 kg/m2) tiveram altura navicular, ângulo do arco longitudinal medial e linha de Feiss medida nas posições neutra e relaxada. A correlação entre eles foi avaliada pelo teste de Pearson. Resultados: Houve uma correlação muito forte das medidas de linha de Feiss de 102 pés entre a posição neutra e relaxada (r = 0,81) e uma correlação moderada entre o ângulo do arco longitudinal medial (r = 0,78) e altura navicular nas posições neutra e relaxada (r = 0,76). Conclusão: As medidas do arco medial longitudinal entre as posições neutra e relaxada estão fortemente correlacionadas. Não é necessário, portanto, medir o arco longitudinal medial nas posições neutra e relaxada. ***Nível de Evidência II, Estudos diagnósticos – Investigação de um exame para diagnóstico.***

Descritores: *Tornozelo. Pé Chato. Pé. Deformidades do Pé. Pé Cavo. Ossos do Tarso.*

Citation: Persiane AS, Negrão DMG, Alves RDP, Freitas DG, Cazarini C Jr., Alves VLS. Subtalar joint in neutral and relaxed positions for evaluation of medial longitudinal arch. Acta Ortop Bras. [online]. 2021;29(4):177-180. Available from URL: http://www.scielo.br/aob.

INTRODUCTION

The biomechanics of the feet interfere with body posture and with the harmonious distribution of joint and plantar pressures, helping to walk within physiological patterns.[1,2] The structure and movements of the arches of the foot are essential for the proper function of the body and well-being.[3]

The medial longitudinal arch (MLA) is the main load-bearing and shock-absorbing structure of the foot. Changes in MLA can cause pain and influence the biomechanics of the limb, leading

All authors declare no potential conflict of interest related to this article.

The study was conducted at Serviço de Fisioterapia da Irmandade da Santa Casa de Misericórdia de São Paulo.
Correspondence: Vera Lúcia dos Santos Alves. Rua Dr. Cesário Mota Júnior, 112, São Paulo, SP, Brazil, 01221020. fisioterapiasc@uol.com.br

Article received on 07/13/2020, approved on 09/24/2020.

to further modifications in plantar pressures that are common in individuals suffering from pathologies in the feet and even in other joints of the lower limbs.[4,5]

The decrease in MLA height, characterized by pronation, reduces the stability of the foot during the support phase and the gait impulse.6 This reduction leads to a decrease in blood flow in the calcaneus tendon,7 which is a risk factor for calcaneal tendinopathy8 and plantar fasciitis, and it is a repetitive strain injury causing excessive deformation of the plantar arch.[6-8]

Several measures are used to evaluate the MLA, such as Feiss line (FL),[9] the navicular height (NH),[9] the medial longitudinal arch angle (MLAA),[9] the arch index,[10] the Foot Posture Index (FPI)[11] and the relative arch deformity.[12] The most common measurements used are the FL, NH and MLAA.[9]

Two measurements have been recommended, the first with the subject sitting, with the subtalar joint in the neutral position and the second in a standing position with bipedal support with the foot relaxed.[12,13] To our knowledge, there are no studies in the literature on the correlation between the measurements (FL, NH, MLAA) with the subtalar in a neutral and relaxed position. This comparison might be important for more specific and efficient assessments, reducing time and costs. Therefore, our study aimed to analyze the correlation between the measurements of the MLA in neutral and relaxed positions.

MATERIALS AND METHODS

Study design and ethics

This is a cross-sectional study, performed with healthy subjects recruited by the social media profile of a university hospital. The university review board (RB) approved the study protocol that was in accordance with the Helsinki Declaration, and all participants signed informed consent forms (RB protocol: 62766716.4.0000.5479).

Participants

Social media profiles from the university hospital were used to recruit participants for this study. The posts invited sedentary adults aged 18 to 40 years and without any feet pain or other symptoms to participate and be evaluated by a physical therapist. Individuals would be excluded if, in the first assessment, they reported a history of feet pain or injury, any lower limb fracture, any muscle or joint lesion or lower limb surgery in the past 12 months, back pain in the last 12 months, rigid flat feet, calcaneus valgus above 10°, or a history of neurological abnormalities. For this initial evaluation, the subjects filled a questionnaire on the demographic and clinical history, including past injuries to the foot.

Evaluation procedures

The same physical therapist, who had five years of experience in orthopedic physical therapy, evaluated all participants between January and July 2017. The training was conducted twice a week for two weeks. The evaluator was trained in the palpation of anatomical structures, how to identify the reference points, the different measurements and the most frequent measurement errors. However, the physical therapist was not informed about the use of the measures, with the purpose to blind for the study objectives.

The evaluator analyzed ten subjects healthy in the pilot study twice, with a one-week interval, so that between-day reliability could be estimated. If the intraclass correlation coefficient (ICC) were < 0.4, the evaluation would not be selected for the study. First, the evaluator measured the calcaneus angle, with the patient lying in a prone position with feet off the bed. He palpated the calcaneus medially and laterally palpated and the inferior and medial aspects of the calcaneus were identified with dots with a marking pen. A line connected the dots, bisecting the calcaneus. The examiner then identified the subtalar neutral by palpating the patient's talus, feeling both medial and lateral aspects equally. He used the goniometer to measure the varus or valgus of the calcaneus.[14]

With the participant sitting on a chair, with hips, knees and ankle bent in 90º, the evaluator identified the following anatomical points using the marker pen: the center of the medial malleolus, the navicular tuberosity and the head of the first metatarsal. Next, the evaluator palpated the lateral and medial aspects of the talus, maintaining the subtalar joint in a neutral position, and then performed the following measurements: MLA angle (MLAA), navicular height (NH) and Feiss line (FL), in this sequence. With the participant now in the standing position, with bipedal support, the evaluator again performed the MLAA, NH and FL measurements with the subtalar joint in a relaxed position.

The evaluator used a goniometer with a transparent plastic protractor (0º to 360º) with two 20 cm rulers for the measurements (SH5205, Carci, São Paulo, Brazil); and a transparent ruler (0 cm to 30 cm; Ruler 30 cm, Acrimet, São Bernardo do Campo, Brazil). For the NH, the evaluator measured the distance from the floor to the navicular tuberosity.[9] For the FL, the evaluator traced a line between the center of the medial malleolus and the head of the first metatarsal. Next, the evaluator used a ruler to measure the perpendicular distance in centimeters between the tubercle of the navicular and the line of the medial malleolus to the head of the first metatarsal. If the tuberosity of the navicular was above the line, the measurement was considered as positive. If the navicular tuberosity was below the line, the value was negative.[9] To measure the MLAA, the evaluator placed the center of the goniometer on the navicular tuberosity, so that the goniometer extremities could indicate the center of the medial malleolus and the head of the first metatarsus.[9] Typical values for NH are between 3.6 and 5.5 cm, for MLAA between 130° and 152° and for FL between -2.6 and 1.2 cm.[9] Figure 1 shows the measurement technique.

Figure 1. Measurement technique of the medial longitudinal arch (MLA). A: Navicular height; B: medial longitudinal arch angle; C: Feiss line.

Sample size and statistical analysis

Ten participants were used as a pilot evaluation to estimate the sample size. This estimating was based on Pearson's correlation analysis between measurements in neutral and relaxed positions, adopting a correlation of at least 0.4, with an alpha of 5% and power of 80%. The estimating revealed that 47 participants would be necessary.

The ten participants of the study were tested on 2 occasions separated by 7 days to determine the test-retest reliability of the ALM measurement. For standard error measurement (SEM), the standard difference (SD) between measurement of first and second day (test score-retest score = difference) were estimated. Next, the obtained SD was multiplied by the square root (1 – ICC).

The intraclass correlation coefficient (ICC) and standard error of measurement (SEM) were 0.98 and 0.15° for MLAA for neutral positions, 0.98 and 0.11° for MLAA for relaxed positions, 0.97 and 0.02 cm for NH neutral positions, 0.92 and 0.06 cm for NH for relaxed positions, 0.89 and 0.07 cm for FL for neutral positions and 0.93 and 0.05 cm for FL relaxed positions.

The Shapiro-Wilk test was used for homogeneity distribution, and a 5% significance level was used, in which the values presented a normal distribution.

Pearson's correlation was used for the analysis of correlation between neutral and relaxed positions. For the interpretation of the Pearson's correlation, 1 was used as the perfect correlation, 0.8 to 0.9 as very strong, 0.6 to 0.7 as moderate, 0.3 to 0.5 as fair, 0.1 to 0.2 as poor and 0 as none. Data were analyzed using SPSS software version 20 (IBM Corporation – Chicago, IL).

RESULTS

During the recruitment period, 54 patients presented to the service to be evaluated. Among these, 51 participants were considered eligible for evaluation, and all of them completed the study. Their mean age was 28 years (with a standard deviation, SD, of 5), most were 36 females (70%), their mean height was 1.66 meters (SD 0.10), the weight was 68.5 kg (SD 17.3), and the body mass index (BMI) was 24.5 kg/m^2 (SD 4.5).

Table 1 shows the mean measurements and standard deviations of the MLAA (medial longitudinal arch angle), NH (navicular height) and FL (Feiss line) in neutral and relaxed positions. The correlation was very strong between the neutral and the relaxed positions of FL (r = 0.81), and moderate for MLAA (r = 0.78) and for NH (r = 0.76), as detailed in Table 2.

Table 1. Results of the tests in neutral and relaxed positions (n = 102 feet).

Test	Mean	Standard deviation	Range
MLAA in neutral (°)	147	9	120 to 172
MLAA in relaxed (°)	145	8	126 to 168
NH in neutral (cm)	5.1	0.7	3.3 to 6.7
NH in relaxed (cm)	4.3	0.8	2.7 to 6.8
FL in neutral (cm)	-1.8	0.8	-3 to 1.5
FL in relaxed (cm)	-1.7	0.9	-3 to 2.3

MLAA: medial longitudinal arch angle; NH: navicular height and FL: Feiss line. Negative numbers mean the navicular tuberosity was below the line between center of the medial malleolus and the head of the first metatarsus.

Table 2. Pearson's correlation between the measurements of the foot medial longitudinal arch (n = 102 feet).

	MLAA neutral	MLAA relaxed	NH neutral	NH relaxed	FL neutral	FL relaxed
MLAA neutral	1					
MLAA relaxed	0.78*	1				
NH neutral	1*	0.47*	1			
NH relaxed	1*	0.47*	0.76*	1		
FL neutral	0.39*	0.38*	0.25†	0.21†	1	
FL relaxed	0.40*	0.38*	0.28*	0.24†	0.81*	1

MLAA: medial longitudinal arch angle; NH: navicular height and FL: Feiss line; *$p < 0.01$; †$p < 0.05$.

DISCUSSION

To the best of our knowledge, ourthis study is the first assessing the correlation between measurements of the subtalar joint in the neutral and relaxed positions, to evaluate the real need to maintain the two evaluations in the physiotherapeutic routine procedure. A strong correlation was found between the neutral and the relaxed positions of FL, and moderate for MLAA and NH. This correlation suggests that the measurements with the relaxed articulation can predict the results of the measurement with the joint in the neutral position and vice versa.

In our study, we were careful to hide the real objective from the physical therapist performing the evaluation. This evaluator was informed that all measurements should be made considering service routine, i.e., in the neutral and relaxed positions, to assess participants for the inclusion in a clinical study. Therefore, the evaluator was not trying to approximate the two measurements and was, in fact, trying to make accurate measurements. This blinding is a strength of this study.

The measurements of the subtalar joint can be a challenge for the professionals in the neutral position. Specialists are able to find the neutral position more frequently than students in 90% of the cases.[15] A cadaveric study has also shown that the joint is not really in the neutral when the traditional concept of neutral position is applied by palpation of the lateral and medial aspects of the talus.[16] Maybe this difficulty in performing the evaluation explains why Holmes, Wilcox and Fletcher[17] found a significant difference between the NH measurements in neutral and relaxed positions. Scholz et al.[18] found a high correlation between the arch height index between the neutral and relaxed positions of the subtalar in 172 feet of children, corroborating the findings this study, but in a different population and with a different measurement. Studies[16-20] aiming to correlate the MLAA measurements with the relaxed subtalar during gait[16] and race[20] support phases, measured by 2D kinematics, have found a strong correlation between the measures, concluding that the static measurement in the relaxed position can predict the same measurement in the support phase of the march and the race.

Based on the previous studies and these findings, this study shows that there is no need to use two measures for MLA. Only the measure in the relaxed position is necessary, because this measure is highly correlated with the dynamic measurement. Measuring only once saves time in the evaluation process and expenditures. Measuring the arch in the relaxed position makes the evaluation process more reliable, considering the risk of bias related to the measurement with the subtalar in a neutral position.

One limitation of the present study is that the non-zero value before the ruler was not removed, providing a different measure of the real in the measurements of NH and FL. Another possible limitation

of our study was that it did not estimate a correlation for the MLA measurements based on participants with a normal, low and high arch, but the normalization of the data was for Danish participants who worked for long periods of standing.[9] Another limitation is that the sequence of measurement of the ALM was not randomized.

Further studies should address not only the comparison of neutral and relaxed positions but also make these comparisons during dynamic activities such as walking, running, jumping, climbing up and going downstairs, since deformation of the MLA occurs as a result of dynamic activities. Besides comparing static and dynamic measures with the FPI, future studies should seek important clinical correlations, although FPI is a subjective visual evaluation and has a low relation with the dynamic analysis.[11]

CONCLUSION

Based on the results our study, we conclude that it is not necessary to use measures in the neutral and relaxed position of the subtalar joint, and that the measurement in the relaxed position is enough for the clinical measurements of the medial longitudinal arch.

AUTHORS' CONTRIBUTIONS: Each author contributed individually and significantly to the development of this article. ASP: study design, experimental study planning, data analysis and interpretation, manuscript writing and final review; DMGN: data interpretation and final review; RDPA: data collection and final review; DGF: study design and critical review of the manuscript; CCJ: study design, data interpretation and manuscript writing; VLSA: study design, experimental study planning and critical review of the manuscript.

REFERENCES

1. Williamson P, Lechtig A, Hanna P, Okajima S, Biaggane P, Nasr M, et al. Pressure distribution in the ankle and subtalar joint with routine and oversized foot orthoses. Foot Ankle Int. 2018;39(8):994-1000.
2. Buldt AK, Allan JJ, Landorf KB, Menz HB. The relationship between foot posture and plantar pressure during walking in adults: A systematic review. Gait Posture. 2018;62:56-67.
3. Stearne SM, McDonald KA, Alderson JA, North I, Oxnard CE, Ruberson J. The foot's arch and the energetics of human locomotion. Sci Rep. 2016;6:19403.
4. Koldenhoven RM, Feger MA, Fraser JJ, Saliba S, Hertel J. Surface electromyography and plantar pressure during walking in young adults with chronic ankle instability. Knee Surg Sports Traumatol Arthrosc. 2016;24(4):1060-70.
5. Wilson JD, Elis ED, Kernozek TW. Plantar loading characteristics during walking in females with and without patellofemoral pain. J Am Podiatr Med Assoc. 2015;105(1):1-7.
6. McKeon PO, Hertel J, Bramble D, Davis I. The foot core system: a new paradigm for understanding intrinsic foot muscle function. Br J Sports Med. 2015;49(5):290.
7. Wezenbeek E, Willems TM, Mahieu N, Van Caekenberghe I, Witvrouw E, De Clercq D. Is Achilles tendon blood flow related to foot pronation? Scand J Med Sci Sports. 2017;27(12): 1970-7.
8. Wezenbeek E, Willems T, Mahieu N, De Muynck M, Bossche LV, Steyaert A, et al. The role of the vascular and structural response to activity in the development of achilles tendinopathy: a prospective study. Am J Sports Med. 2018;46(4):947-54.
9. Nilsson MK, Friis R, Michaelsen MS, Jakobsen PA, Nielsen RO. Classification of the height and flexibility of the medial longitudinal arch of the foot. J Foot Ankle Res. 2012;5:3.
10. Hollander K, Stebbins J, Albertsen IM, Hamacher D, Babin K, Hacke C, Zech A. Arch index and running biomechanics in children aged 10-14 years. Gait Posture. 2018;61:210-4.
11. Paterson KL, Clark RA, Mullins A, Bryant AL, Mentiplay BF. Predicting dynamic foot function from static foot posture: comparison between visual assessment, motion analysis, and a commercially available depth camera. J Orthop Sports Phys Ther. 2015;45(10):789-98.
12. Birinci T, Demirbas SB. Relationship between the mobility of medial longitudinal arch and postural control. Acta Orthop Traumatol Turc. 2017;51(3):233-7.
13. Feiss HO. A simple method of estimating the common variations and deformities of the foot. Am J Med Sci. 1909;138(2):213-30.
14. Cook CE, Hegedus EJ. Orthopedic Physical Examination Tests: An Evidence--Based Approach. 2nd ed. New Jersey: Pearson Education; 2013.
15. Pierrynowski MR, Smith SB, Mlynarczyk JH. Proficiency of foot care specialists to place the rearfoot at subtalar neutral. J Am Podiatr Med Assoc. 1996; 86(5):217-23.
16. Chen YX, Yu GR, Mei J, Zhou JQ, Wang W. Assessment of subtalar joint neutral position: a cadaveric study. Chin Med J (Engl). 2008;121(8):735-9.
17. Holmes CF, Wilcox D, Fletcher JP. Effect of a modified, low-dye medial longitudinal arch taping procedure on the subtalar joint neutral position before and after light exercise. J Orthop Sports Phys Ther. 2002;32(5):194-201.
18. Scholz T, Zech A, Wegscheider K, Lezius S, Braumann KM, Sehner S, et al. Reliability and Correlation of Static and Dynamic Foot Arch Measurement in a Healthy Pediatric Population. J Am Podiatr Med Assoc. 2017;107(5):419-27.
19. McPoil TG, Ford J, Fundaun J, Gallegos C, Kinney A, McMillan P, et al. The use of static measure to predict foot posture at midstance during walking. Foot (Edinb). 2016;28:47-53.
20. Bade MB, Chi TL, Farrell KC, Gresl AJ, Hammel LJ, Koster BN, et al. The use of a static measure to predict foot posture at midsupport during running. Int J Sports Phys Ther. 2016;11(1):64-71.

DOI: http://dx.doi.org/10.1590/1413-785220212904237078

A POST-TREATMENT RETROSPECTIVE EVALUATION OF SLIPPED CAPITAL FEMORAL EPIPHYSIS

AVALIAÇÃO PÓS-TRATAMENTO DE EPIFISIÓLISE PROXIMAL DO FÊMUR: ESTUDO RETROSPECTIVO

Gustavo Remigio Gomes[1], David Israel de Carvalho Nascimento[1], Davi Coutinho Fonseca Fernandes Gomes[1,2], Lucas Henrique Araujo de Oliveira[2], Túlio Vinícius de Oliveira Campos[1,2], Marco Antonio Percope de Andrade[1,2]

1. Hospital das Clínicas da Universidade Federal de Minas Gerais, Belo Horizonte, MG, Brazil.
2. Hospital Risoleta Tolentino Neves, Belo Horizonte, MG, Brazil.

ABSTRACT

Objective: To analyze the cases of slipped capital femoral epiphysis (SCFE) submitted to surgery at the Pediatric Orthopedics Surgery service of the Hospital Risoleta Tolentino Neves (HRTN), Belo Horizonte/MG, between 2016 and 2019. Methods: Patients treated for SCFE at the HRTN between January/2016 and January/2019 participated in this study. The following data were collected: gender, age, affected side, procedure performed, and postoperative complications. Results: Twenty-one patients were treated at HRTN during the specified period. Among these, most were female (57%) with mean age of 12 years. At the initial diagnosis, about 80% of the patients presented with chronic/acute-on-chronic epiphysis. The left hip was slightly more affected than the right (6:5), with a bilateral rate of 47%, and avascular necrosis was the most frequent complication, occurring in 33% of cases. Conclusion: Slipped femoral capital epiphysis is associated with high morbidity; thus, early diagnosis, endocrine disorder investigation, and appropriate surgical treatment are key for improving these patients' clinical and functional outcome. ***Level of Evidence II, Retrospective study.***

Keywords: Slipped Capital Femoral Epiphysis. Hip. Child.

RESUMO

Objetivo: Analisar os casos de epifisiólise do fêmur proximal operados pelo serviço de Ortopedia Pediátrica do Hospital Risoleta Tolentino Neves (HRTN), Belo Horizonte/MG, entre os anos de 2016 e 2019. Métodos: Foram analisados retrospectivamente os pacientes submetidos a tratamento cirúrgico de epifisiólise no Hospital Risoleta Tolentino Neves entre janeiro/2016 a janeiro/2019. Os dados coletados para análise foram: sexo, idade, lado acometido, cirurgia realizada, complicações pós-operatórias. Resultados: De janeiro de 2016 a janeiro de 2019, foram tratados 21 pacientes no HRTN. Houve predomínio do sexo feminino (57%), com média de idade de 12 anos. Cerca de 80% dos pacientes apresentaram quadro de epifisiólise crônica/ crônica-agudizada no primodiagnóstico. O lado esquerdo foi ligeiramente mais acometido em relação ao direito (6:5), com bilateralidade de 47%. A necrose avascular foi a complicação mais frequente, em 33% dos casos. Conclusão: Trata-se de quadro de alta morbidade associada, devendo haver um diagnóstico precoce, investigação de distúrbios endócrinos e tratamento cirúrgico adequado, visando uma melhora do prognóstico clínico e funcional do paciente. ***Nível de Evidência II, Estudo retrospectivo.***

Descritores: *Escorregamento das Epífises Proximais do Fêmur. Quadril. Criança.*

Citation: Gomes GR, Nascimento DIC, Gomes DCFF, Oliveira LHA, Campos TVO, Andrade MAP. A post-treatment retrospective evaluation of slipped capital femoral epiphysis. Acta Ortop Bras. [online]. 2021;29(4):181-183. Available from URL: http://www.scielo.br/aob.

INTRODUCTION

Proximal femoral epiphysis, or slipped capital femoral epiphysis (SCFE), is an important disorder of adolescence and the most common cause of hip pain and dysfunction in this period of life. SCFE often develops during pubertal growth, being a topic of great interest in pediatric orthopedics. Among the several genetic, endocrine, and biomechanical risk factors for SCFE described in the literature, obesity and decrease in femoral anteversion are considered the most relevant.[1]

Proximal femoral epiphysis comprises a change in the normal anatomical relationship between the femoral head and neck, whereby the femoral neck deviates anterosuperiorly in relation to the femoral head at the level of the growth plate (physis). According to the literature,[2] SCFE affects mostly male patients (2:1 - 3:2) and the left hip. Bilaterality occurs in 20% to 40% of the cases, 50% of which presents symptoms and contralateral changes at the time of diagnosis. The incidence of SCDE in Brazil is 0.7-3.41 cases per 100,000 individuals, peaking among individuals aged from 11-15 years.[3]

All authors declare no potential conflict of interest related to this article.

The study was conducted at Hospital Risoleta Tolentino Neves.
Correspondence: Gustavo Remigio Gomes. Rua Marabá, Belo Horizonte, MG, Brazil, 30350160. gustavoremigiogomes@gmail.com

Article received on 03/28/2020, approved on 08/27/2020.

Surgical treatment of SCFE seeks to stabilize the proximal femoral epiphysis in the femoral neck, preventing further slippage, reducing deformity, or even promoting physeal closure.[2]
Premature physeal closure, chondrolysis, avascular necrosis of the femoral head, femoroacetabular impingement, hip deformity, and premature coxarthrosis are the most common complications associated with the condition and its treatment.[4]
This study aims to analyze SCFE cases submitted to surgery at the Pediatric Orthopedics Surgery service of the Hospital Risoleta Tolentino Neves between 2016 and 2019 based on initial examination, surgical procedure, and clinical outcome.

MATERIALS AND METHODS

This is a retrospective study conducted with patients treated for slipped capital femoral epiphysis at the Hospital Risoleta Tolentino Neves between January/2016 and January/2019. Data were collected from medical records, pre and postoperative radiographs, and hospital records on Orthotics, Prosthetics, and Special Materials (OPMEs). The following data were analyzed: gender, age at diagnosis, affected side, surgical procedure performed, postoperative complications, and functionality after one year.

RESULTS

Twenty-one patients were treated for slipped capital femoral epiphysis (SCFE) at the Hospital Risoleta Tolentino Neves (HRTN) between January, 2016 and January, 2019. Among these, most were female (57%), 12 years as the mean age, and 80% presented with chronic/acute-on-chronic epiphysis at the initial diagnosis. The left hip was slightly more affected than the right (6:5), with a bilateral rate of 47% (Tables 1 and 2; Figure 1).

Table 1. Characteristics of patients who underwent surgical treatment (N; %).

Variable	N	%
Gender		
Male	9	42.9
Female	12	57.1
Age		
9 years old	1	4.8
10 years old	3	14.3
11 years old	3	14.3
12 years old	6	28.6
13 years old	3	14.3
14 years old	2	9.5
15 years old	3	14.3
Mean age	12	
Laterality		
Right side	5	23.8
Left side	6	28.6
Bilateral	10	47.6
Clinical classification		
Acute	3	14.3
Chronic	12	57.1
Acute-on-chronic	6	28.5
Interventions		
Cannulated screw fixation	15	71.4
Contralateral prophylactic fixation	4	19.0
Modified Dunn procedure	7	33.3
Outcome		
Avascular necrosis of the femoral head	7	33.3
Femoral neck fracture	1	4.8
Cam-type femoroacetabular impingement	1	4.8

Table 2. Patient's age by gender and for the general population.

Statistics	Male	Female	General
Mean (SD)	13.7 (1.2)	11.1 (1.2)	12.2 (1.7)
Median (IQR)	14 (2)	11 (2)	12 (2)
Min; Max	12; 15	9; 13	9; 15

Note: significant age differences between genders (mean and median). $p < 0.001$; SD: standard deviation; IQR: interquartile range.

One year after surgery, patients presented a slight decrease in internal rotation (less than 10 degrees in relation to the contralateral limb), but without functional impairment, being able to return to daily recreational activities.

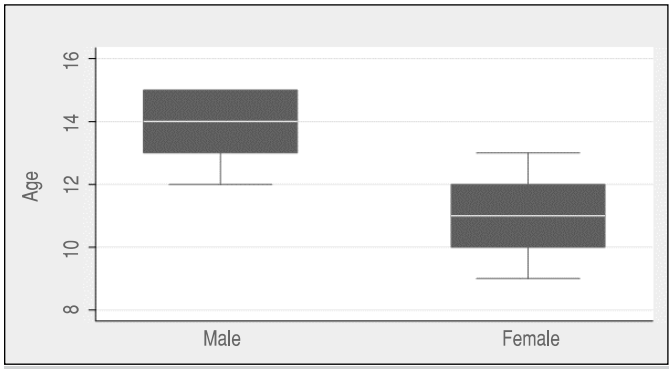

Figure 1. Boxplot representing age distribution by gender.

Avascular necrosis of the femoral head (ANFH) was the most common complication, occurring in 33% of the cases, followed by femoroacetabular impingement and femoral neck fracture. One patient evolved with ANFH and substantial limitations in hip flexion and internal rotation, thus being a potential candidate for total hip arthroplasty in the future.

DISCUSSION

The clinical presentation of epiphysis is often nonspecific, but patients affected by the condition often present claudication and poorly localized pain in the hip, thigh, and knee. In total, 15% of cases include knee pain.[5] Slipped capital femoral epiphysis (SCFE) is classified using the Loder classification, which assesses stability and functional status based on patients' weight-bearing tolerance with or without the aid of crutches. Fahey and O'Brian propose yet another classification system, whereby SCFE is classified according with symptoms onset and duration: when symptoms started less than three weeks prior to diagnosis, the condition is considered acute; when symptoms appeared and persisted for more than 3 weeks, it is considered chronic; and when chronic symptoms get worse, it is considered acute-on-chronic.[6]
About 85% of the analyzed patients presented with a chronic or acute-on-chronic condition at the time of surgery, which may be associated with delay in diagnosis and referral to a specialized service. The mean age was higher among male patients (12 years) than among female patients (11.2 years), which is consistent with literature data. Approximately 25% of the cases showed bilaterality, ranging from 8 to 50%.[7]
Surgical treatment options included *in situ* cannulated screw fixation, proximal femoral osteotomies (subcapital, base of the femoral neck, or intertrocanteric), and prophylactic fixation.
Whereas *in situ* fixation is indicated for mild and stable slips, more severe epiphyseal slips require osteotomies to restore hip anatomy and reduce the risk of avascular necrosis of the femoral head.

Subcapital osteotomies (modified Dunn) have been shown to provide good clinical and radiographic outcomes for treating severe and unstable slips when compared to *in situ* fixation.[8]

In turn, prophylactic fixation of a clinical and radiographically normal hip is indicated for patients who are underage, obese, presenting with endocrinopathies, and for those whose follow-up is considered difficult. The ongoing debate on routine prophylactic contralateral fixation has pointed to tendencies for increasing this practice, as the morbidity and complication rates associated with the procedure are lower in relation to the development of contralateral disease.[9]

In a long-term study conducted by Hägllund, 25% of the patients who did not undergo prophylactic fixation developed contralateral hip osteoarthritis.[10] In our study, 19% of the patients underwent prophylactic fixation, showing good postoperative clinical evolution after one year.

Avascular necrosis was the most common complication found our study sample, which may be explained by the late diagnosis, especially when considering the significant relationship between epiphyseal slips severity and delay in diagnosis delay.[2]

CONCLUSION

Our results show that epiphysis is a common hip pathology in children and adolescents, and late diagnosis may impact the treatment, morbidity, and prognosis of these patients. Thus, health professionals, especially those in primary care, must be attentive to children and adolescents with hip or knee pain, promptly referring them for a pediatric orthopedist for an appropriate surgical treatment.

Due to being a condition that implies high morbidity, epiphyseal slips must be surgically stabilized in patients presenting clinical and laboratory conditions for the procedure.

Physicians, pediatricians, and orthopedists must also be aware of possible associated endocrine disorders such as hypothyroidism and renal failure, investigating them at the time of diagnosis, especially in patients with early involvement.

AUTHORS' CONTRIBUTIONS: Each author contributed individually and significantly to the development of this article. GRG: data analysis and interpretation, writing of the article; DICN: data analysis and interpretation, writing of the article; DCFFG: surgeries performance and data analysis; LHAO: surgeries performance and data analysis; TVOC: intellectual concept and review of the article; MAPA: intellectual concept and review of the article.

REFERENCES

1. Hellmich HJ, Krieg AH. [Slipped capital femoral epiphysis-etiology and pathogenesis]. Orthopade. 2019;48(8):644-50. German.
2. Herring JA. Tachdijan's pediatric orthopaedics: From the Texas Scottish Rite Hospital for Children. 5th ed. Philadelphia: Saunders; 2014.
3. Kotzias Neto, A. Epifisiólise proximal do fêmur. In: Hebert SK, Barros Filho TEP, Xavier R, Pardini AG Jr, organizadores. Ortopedia e traumatologia: Princípios e Práticas. 5a ed. Porto Alegre: Artmed; 2017. p. 300-19.
4. Johns K, Tavarez MM. Slipped Capital Femoral Epiphysis. In: StatPearls [Internet]. Treasure Island (FL): StatPearls Publishing; 2020.
5. Matava MJ, Patton CM, Luhmann S, Gordon JE, Schoenecker PL. Knee pain as the initial symptom of slipped capital femoral epiphysis: an analysis of initial presentation and treatment. J Pediatr Orthop. 1999;19(4):455-60.
6. Georgiadis AG, Zaltz I. Slipped capital femoral epiphysis: how to evaluate with a review and update of treatment. Pediatr Clin North Am. 2014;61(6):1119-35.
7. Loder RT, Skopelja EN. The epidemiology and demographics of slipped capital femoral epiphysis. ISRN Orthop. 2011;2011:486512.
8. Novais EN, Maranho DA, Heare T, Sink E, Carry PM, O'Donnel C. The modified Dunn procedure provides superior short-term outcomes in the treatment of the unstable slipped capital femoral epiphysis as compared to the inadvertent closed reduction and percutaneous pinning: a comparative clinical study. Int Orthop. 2018;43(3):669-75.
9. Woelfle JV, Fraitzl CR, Reichel H, Nelitz M. The asymptomatic contralateral hip in unilateral slipped capital femoral epiphysis: morbidity of prophylactic fixation. J Pediatr Orthop B. 2012;21(3):226-9.
10. Hägglund G. The contralateral hip in slipped capital femoral epiphysis. J Pediatr Orthop B. 1996;5(3):158-61.

DOI: http://dx.doi.org/10.1590/1413-785220212904235714

COMPARISON OF HEMOSTASIS WITH TRANEXAMIC ACID IN TOTAL KNEE ARTHROPLASTY

COMPARAÇÃO DA HEMOSTASIA COM ÁCIDO TRANEXÂMICO EM ARTROPLASTIA TOTAL DE JOELHO

Otávio Montovanelli Monteiro[1], Rodrigo Turra Perrone[1], Fabrício Nascimento Almeida[1], Cid Pereira de Moura Junior[1], Saulo Gomes de Oliveira[1], Gustavo Dalla Bernardina de Almeida[1]

1. Hospital da Santa Casa de Misericórdia de Vitória, Vitória, ES, Brazil.

ABSTRACT

Objective: To compare the use of intravenous and topical tranexamic acid (TXA) in unilateral primary total knee arthroplasty (TKA) in relation to blood loss and complications inherent to the medication. Method: Three groups with 14 patients each were constituted, and all of them were operated using the same surgical technique. In Group 1, usual measures for bleeding control were performed. Group 2 patients received TXA topically on the joint surface. In Group 3, intravenous TXA was used. Hemoglobin (HB), hematocrit (HTC), platelets (PLAT), prothrombin time, activated partial thromboplastin time and volume of blood drained observed 24 hours after arthroplasty were compared to the values of tests found before surgery. Results: There was a decrease in the concentration of HB, HTC and PLAT in all groups in relation to the preoperative, however without significant difference. Group 3 had a lower mean volume of drained blood than the other groups, with statistical significance. No adverse effects or thromboembolic events were observed in the groups that received TXA. Conclusion: This study showed superiority in the use of intravenous TXA in decreasing the volume of bleeding, without increasing the risk of thromboembolic events. ***Level of Evidence I, High quality randomized trial with statistically significant difference or no statistically significant difference but narrow confidence intervals.***

Keywords: Tranexamic Acid. Arthroplasty. Knee. Hemorrhage. Antifibrinolytic Agents. Osteoarthritis, Knee.

RESUMO

Objetivo: Comparar o uso do ácido tranexâmico (ATX) intravenoso e tópico em artroplastia total de joelho primária (ATJ) unilateral em relação à perda sanguínea e complicações inerentes à medicação. Métodos: Três grupos com 14 pacientes cada foram divididos, todos operados utilizando-se a mesma técnica cirúrgica. No Grupo 1, medidas habituais para controle do sangramento foram realizadas. Pacientes do Grupo 2 receberam ATX topicamente na superfície articular. Já no Grupo 3, foi utilizado ATX intravenoso. Hemoglobina (HB), hematócrito (HTC), plaquetas (PLAQ), tempo de protrombina, tempo de tromboplastina parcialmente ativada e volume de sangue drenado observados 24 horas após a artroplastia foram comparados aos valores dos exames encontrados antes da cirurgia. Resultados: Houve queda da concentração de HB, HTC e PLAQ em todos os grupos em relação ao pré-operatório, sem, contudo, diferença significante. O Grupo 3 apresentou menor volume médio de sangue drenado do que os demais grupos, com significância estatística. Não foram observados efeitos adversos ou eventos tromboembólicos nos grupos que receberam o ATX. Conclusão: O presente estudo demonstra superioridade da utilização de ATX intravenoso em diminuir o volume de sangramento, sem aumentar o risco de eventos tromboembólicos. ***Nível de Evidência I, Estudo clínico randomizado de alta qualidade com ou sem diferença estatisticamente significante, mas com intervalos de confiança estreitos.***

Descritores: *Ácido Tranexâmico. Artroplastia. Joelho. Hemorragia. Antifibrinolíticos. Osteoartrite do Joelho.*

Citation: Monteiro OM, Perrone RT, Almeida FN, Moura Junior CP, Oliveira SG, Almeida GDB. Comparison of hemostasis with tranexamic acid in total knee arthroplasty. Acta Ortop Bras. [online]. 2021;29(4):184-188. Available from URL: http://www.scielo.br/aob.

INTRODUCTION

Osteoarthritis (OA) of the knee is one of the most common causes of disability and its prevalence is increasing as older and obese populations grow.[1, 2] More than 50% of people over the age of 65 have radiographic changes in the knee that indicate OA.[1] The risk of developing OA in the knee is due to a multifactorial and complex interaction of constitutional and mechanical factors.[1]

Initial and conservative treatment can be non-pharmacological, including weight loss, aerobic exercise, osteopathic manipulative treatment, or pharmaceutical treatment.[1] In refractory or advanced cases, total knee arthroplasty (TKA) is now a commonly performed surgical procedure.[2,3] TKA allows the patient to move the knee without pain, in addition to maintaining a wide range of daily activities, permitting them to lead a normal life.[2] However, it is associated with large amounts of

All authors declare no potential conflict of interest related to this article.

The study was conducted at Hospital da Santa Casa de Misericórdia de Vitória.
Correspondence: Otávio Montovanelli Monteiro. Rua Desembargador Augusto Botelho, 645, apto. 304, Vila Velha, ES, Brazil, 29101110. otaviomm88@gmail.com

Article received on 03/28/2020, approved on 08/27/2020.

perioperative blood loss and high blood transfusion rates.[4] The blood loss may come from the osteotomized surface of the distal femur and the proximal tibia, from the release of soft tissues and dredging of the marrow cavity.[5] The use of chronic anticoagulant medication and the early rehabilitation of joint function also results in postoperative anemia, which are common concerns for postoperative complications after TKA surgery.[4,5] This finding has led surgeons and researchers to seek pharmacological and mechanical means to avoid this perioperative blood loss as much as possible and to reduce transfusion rates.

Tranexamic acid (TXA) is a synthetic derivative of the amino acid lysine that inhibits fibrinolysis by competitively blocking plasminogen lysine binding sites.[6] Studies have shown that administration of tranexamic acid decreases bleeding after a series of surgical procedures[7-9] including TKA,[5,8,10] without predisposing to thromboembolic complications.[6, 9, 10]

Thus, the present study compared two methods of administering TXA – topical intra-articular and intravenous – with each other and in relation to a control group, with the main objective of evaluating the effectiveness in reducing bleeding and the need for blood transfusion in patients submitted to unilateral primary TKA, in addition to observing the safe use of TXA (secondary objective).

METHOD

Study design, participation criteria and sample size

This is a prospective, randomized study, initiated after approval by the Human Research Ethics Committee of the Higher School of Sciences of Santa Casa de Misericórdia de Vitória, institution where the surgeries were performed, published on *Plataforma Brasil* with the number of opinion 2,449,068. All procedures are in accordance with the 1995 Helsinki declaration. Patients were invited to participate in the research after being duly informed. All signed the Informed Consent Form. The doctor who followed the evolution of patients after the surgical procedures did not participate in them, and was not informed about which line of treatment the patient had been submitted to, so that there was no influence of results at the time of data collection. The procedures were performed in the operating room of a philanthropic hospital in the city of Vitória, state of Espírito Santo, Brazil, which provided access to patient identification data and treatment lines, so that there could be data analysis at the end of the procedure study.

The study included patients older than 55 years in advanced stage of primary knee osteoarthritis according to the criteria of the American College of Rheumatology[11] and with grade IV radiological changes according to the Kellgren and Lawrence classification.[12] Patients with acute occlusive vasculopathy, hypersensitivity to the components of the tranexamic acid formula, no indication for primary total knee arthroplasty, those who abuse alcohol and medications, and who use glucocorticoids or opioids daily were not included.

The total sample size was 42 patients (N = 42) divided equally in three groups (14 in each). The sample size was calculated for comparison among the three groups using the G-Power program, considering the sample size calculation for fixed event analysis, an effect size of 0.5, significance of 5%, power of the 80% test.

In a previously prepared sealed container, 42 envelopes (14 from each group) were inserted, which were randomly selected by a team member on the day of surgery.

Surgical technique and interventions

All patients underwent primary unilateral total knee arthroplasty with preservation of the posterior cruciate ligament (PCL), using the anteromedial parapatellar approach. Lateral release and patellar cutting were not performed in any of the patients.

In Group 1, TKA was performed and only mechanical and electrical blood coagulation methods were used. Such methods were also used in groups 2 and 3. In Group 2, after TKA, patients received 15 mg/kg of TXA in 100 mL of normal saline that was applied topically to the joint surface and left in contact by 10 minutes before the tourniquet is released. Finally, in Group 3, patients were administered intravenously TXA at a dose of 15 mg/kg, 30 minutes before tourniquet deflation.[3] After that, all patients underwent suture in layers, using the same technique, and the installation of a drain by suction (Portovac 4.8 mm). All patients received enoxaparin in their prophylactic dose to prevent thromboembolic events after surgery.

Patients underwent preoperative laboratory tests 30 days or less before surgery and the values of hemoglobin (HB), hematocrit (HTC), platelets (PLAT), prothrombin time and activated partial thromboplastin time were collected. New laboratory tests were collected 24 hours after surgery (hemoglobin, hematocrit, platelets) and these data were compared with preoperative tests. The drains were removed 24 hours after surgery and the volume of blood drained during this period was recorded.

The pre and postoperative moments for the variables HB, HTC and PLAT were compared. We calculated the variation (delta) for these variables and compared the three groups. We also compared the three groups for the following variables: prothrombin time/activity (PT ATV%), prothrombin time/INR (PT INR), activated partial thromboplastin time (APTT) and volume in ml of blood drained in 24 hours. The need for blood transfusion in the postoperative period and thromboembolic complications were also evaluated.

Outcomes

The study presented as its primary outcome the volume of blood drained 24 hours after the TKA was performed. As secondary outcomes, the levels of HB, HTC, PLAT; the need for blood transfusion; the appearance of thromboembolic complications.

Statistical analysis

The results of this work were analyzed using the Paired T-Student tests, ANOVA, Tukey's Multiple Comparison (post hoc). The level of statistical significance was 5%. For statistical analysis, the following software were used: SPSS V20, Minitab 16 and Excel Office 2010.

RESULTS

We observed that there is a mean difference between the pre and postoperative moments for the variables HB, HTC and PLAT in the three groups, (Tables 1, 2 and 3). We did not observe a statistically significant mean difference between the groups for the variation (delta) of HB, HTC and PLAT (Table 4).

Table 1. Comparing preoperative and postoperative moments by group for hemoglobina.

HB		Mean	Median	Standard Deviation	DC	Min	Max	N	CI	P-value
Group 1	Pre	13.18	12.8	1.24	9%	11.4	15.4	14	0.65	<0.001*
	Post	10.36	10.4	1.25	12%	8.1	12.9	14	0.65	
Group 2	Pre	13.48	13.5	0.94	7%	11.9	15.4	14	0.49	<0.001*
	Post	10.99	11.0	1.06	10%	9.0	12.5	14	0.56	
Group 3	Pre	13.03	13.2	1.19	9%	10.8	14.4	14	0.63	<0.001*
	Post	10.35	10.6	1.62	16%	7.7	13.0	14	0.85	

HB, hemoglobin; Pre, preoperative; Post, postoperative; DC, derivation coefficient; Min, minimum; Max, maximum; N, sample size; IC, confidence interval
*Considered statistically significant

Table 2. Comparing preoperative and postoperative moments by group for hematocrit.

HTC		Mean	Median	Standard Deviation	DC	Min	Max	N	CI	P-value
Group 1	Pre	39.54	39.4	3.68	9%	34.4	45.8	14	1.93	<0.001*
	Post	30.54	30.7	3.35	11%	23.9	36.3	14	1.75	
Group 2	Pre	40.44	40.3	2.81	7%	34.7	45.3	14	1.47	<0.001*
	Post	32.71	32.4	3.37	10%	27.3	38.4	14	1.77	
Group 3	Pre	39.65	40.7	3.70	9%	33.0	44.7	14	1.94	<0.001*
	Post	30.81	30.8	4.84	16%	23.2	38.9	14	2.54	

HTC, hematocrit; Pre, preoperative; Post, postoperative; DC, derivation coefficient; Min, minimum; Max, maximum; N, sample size; IC, confidence interval
*Considered statistically significant

Table 3. Comparing preoperative and postoperative moments by group for platelets.

PLAT		Mean	Median	Standard Deviation	DC	Min	Max	N	CI	P-value
Group 1	Pre	230.607	233.000	51.136	22%	129.000	309.000	14	26.786	<0,001*
	Post	171.500	169.000	37.910	22%	110.000	245.000	14	19.858	
Group 2	Pre	214.286	210.500	48.175	22%	156.000	299.000	14	25.235	0,022
	Post	183.357	178.000	31.532	17%	137.000	236.000	14	16.517	
Group 3	Pre	224.407	233.000	38.426	17%	139.000	292.000	14	20.128	<0,001*
	Post	173.071	180.000	28.261	16%	126.000	219.000	14	14.804	

PLAT, platelets; Pre, preoperative; Post, postoperative; DC, derivation coefficient; Min, minimum; Max, maximum; N, sample size; IC, confidence interval
*Considered statistically significant

Table 4. Comparison of the observed variation of HB, HTC and PLAT between the Groups.

Gain		Mean	Median	Standard Deviation	DC	Min	Max	N	CI	P--value
HB	Group 1	-2.82	-2.66	1.11	39%	-4.50	-1.00	14	0.58	0.756
	Group 2	-2.49	-2.25	1.16	47%	-4.70	-1.10	14	0.61	
	Group 3	-2.68	-2.55	1.19	44%	-5.30	-1.00	14	0.62	
HTC	Group 1	-8.99	-8.90	3.71	41%	-16.10	-2.80	14	1.94	0.570
	Group 2	-7.73	-6.50	3.28	42%	-13.40	-4.10	14	1.72	
	Group 3	-8.84	-8.40	3.26	37%	-14.50	-2.70	14	1.71	
PLAT	Group 1	-59.107	-60.500	29.031	49%	-122.500	-17.000	14	15.207	0.104
	Group 2	-30.929	-17.000	44.517	144%	-138.000	8.000	14	23.319	
	Group 3	-51.336	-58.500	29.693	58%	-91.000	23.000	14	15.554	

HB, hemoglobin; HTC, hematocrit; PLAT, platelets; Pre, preoperative; Post, postoperative; DC, derivation coefficient; Min, minimum; Max, maximum; N, sample size; IC, confidence interval

The comparison of the volume of blood drained (Graph 1) showed a statistical difference between the groups (Table 5). We observed that this difference was made between Group 1 compared to Group 3 (Table 6).

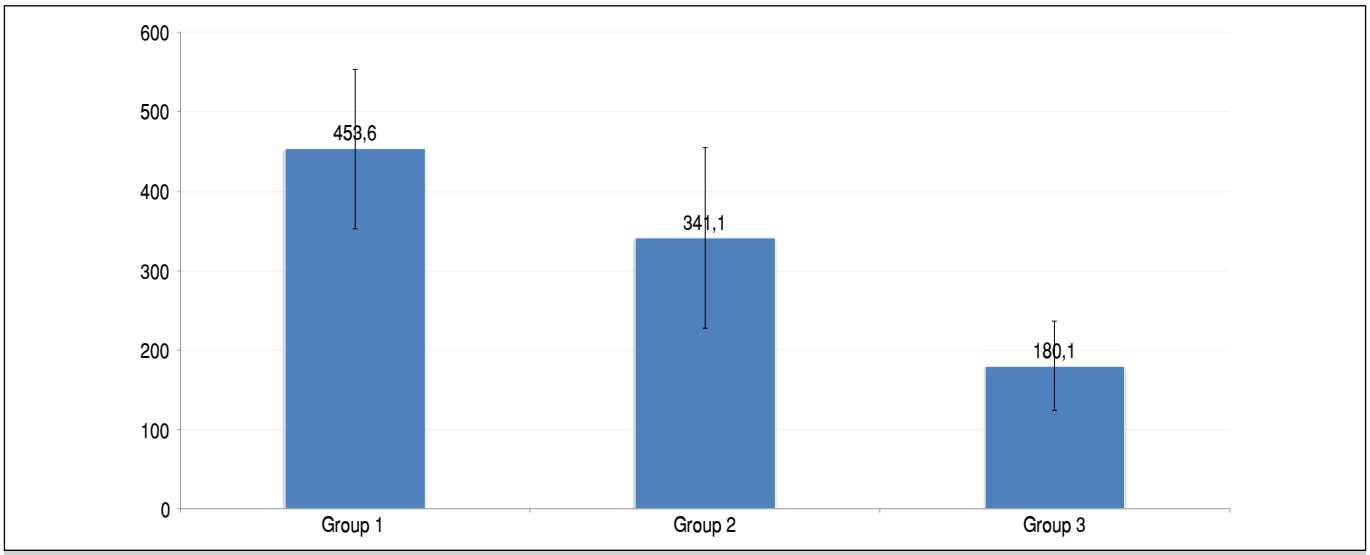

Graph 1. Graph comparing the volume (ml) of blood drained in 24 hours.

Table 5. Comparison of Groups for PT, APTT and Drained Blood (ml).

Groups		Mean	Median	Standard Deviation	DC	Min	Max	N	CI	P-value
PT (ATV%)	Group 1	89.3	88.0	7.3	8%	78.5	100.0	14	3.8	0.516
	Group 2	92.0	93.1	10.9	12%	77.6	115.5	14	5.7	
	Group 3	92.9	95.1	7.3	8%	76.7	100.0	14	3.8	
PT (INR)	Group 1	1.056	1.065	0.068	6%	0.880	1.150	14	0.036	0.377
	Group 2	1.058	1.030	0.082	8%	0.940	1.260	13	0.045	
	Group 3	1.051	1.055	0.052	5%	1.000	1.190	14	0.027	
APTT	Group 1	1.006	1.000	0.121	12%	0.820	1.280	14	0.063	0.288
	Group 2	1.054	1.010	0.077	7%	1.000	1.250	14	0.040	
	Group 3	1.008	1.015	0.063	6%	0.850	1.072	14	0.033	
Drained Blood	Group 1	453.6	475.0	191.9	42%	200.0	710.0	14	100.5	0.001*
	Group 2	341.1	332.5	216.7	64%	100.0	890.0	14	113.5	
	Group 3	180.1	165.0	106.5	59%	55.0	400.0	14	55.8	

PT (ATV%), prothrombin time/activity; PT (INR), prothrombin time/international normalized ratio; APTT, activated partial thromboplastin time; DC, derivation coefficient; Min, minimum; Max, maximum; N, sample size; IC, confidence interval
*Considered statistically significant

Table 6. P-values for blood volume drained (ml) from Table 5.

		Group 1	Group 2
Drained Blood	Group 2	0,229	
	Group 3	0,001*	0,055

*Considered statistically significant

We did not observe any difference among groups for the variables prothrombin time/activity (PT ATV%), prothrombin time/INR (PT INR), activated partial thromboplastin time (APTT).
One patient in the control group had pulmonary thromboembolism. Only one patient in group 3 required blood transfusion in the postoperative period. There were no surgical complications, death or other complications during the experiment.

DISCUSSION

TKA is recognized as a successful procedure, increasingly performed in orthopedics, since the population has aged and needs a better quality of life. However, TKA has some complications that still need a definitive resolution, including intra and postoperative bleeding with consequent hemodynamic[8] and infectious disorders.[13,14]
The use of a tourniquet is capable of considerably diminishing intraoperative bleeding,[15] contributing to decrease hemodynamic effects as well as allowing for cleaner surgery, even facilitating the cementation of implants.[15] However, when it is used, most bleeding in TKA occurs after its release,[16] with no significant difference between its early (before skin suture) or late (after dressing the compressive dressing).[17]
Therefore, the use of pharmacological strategies aimed at reducing bleeding, especially after the release of ischemia, has been both gaining adherents and being the target of several studies. Among these strategies, the use of TXA[2,8,13,18] draws attention.
In addition to elective surgery, TXA is also used successfully, reducing the need for transfusions and death from hypovolemic shock in trauma victims, without increasing the risk of thromboembolic events[9].
The way in which TXA has been administered varies, however[2,5,7-10,13,18]. The present study sought to compare two different strategies for using TXA: topical intra-articular application and intravenous use.
Our results demonstrated that both topical and intravenous use of TXA is safe, since no adverse effects or increased thromboembolic events were observed when compared with the control group. Besides, these results are in line with other studies.[2,5,8,10,13,18]
Our study also demonstrated that the control group had greater blood loss when compared with the groups that received TXA, which is explained by the antifibrinolytic effect of the drug,[6] as well as was verified in other studies[2,5,8,10,13,18] who used TXA in knee arthroplasties in different doses and forms of application.
The study by Aggarwal et al.[2] observed a lower volume of bleeding when topical rather than intravenous TXA was used in bilateral primary knee arthroplasties performed simultaneously.
In our comparison, we evidenced that the intravenous use of TXA was more effective in reducing bleeding in the postoperative period than topical application, with a significant result. The volume of blood drained in 24 hours was, on average, 341.1 ml for group 2 and 180.1 ml for group 3. However, there was no statistically significant decrease in the loss of hemoglobin and hematocrit between the groups. A similar result was also observed in a study alike ours, even though the doses of TXA administered varied.[18] Even so, taking into account the possible complications of hematoma formation, such as infections,[13,14] delayed healing[19] and increased postoperative pain,[14,20] we can infer the advantage of intravenous use of TXA

CONCLUSION

Our study showed superiority in the use of intravenous tranexamic acid in relation to the topical use of tranexamic acid and the control group, in view of the lower volume of blood drained. The use of tranexamic acid proved to be safe, once no possible adverse reactions from its use or thromboembolic events were observed in patients in the groups in which it was administered.

AUTHORS' CONTRIBURTIONS: Each author contributed individually and significantly to the development of this article. OMM: substantial contribution to the work in its conception and design, data collection, analysis and interpretation, writing and critical review of its intellectual content; RTP: substantial contribution to the work in its conception and design, data collection, analysis and interpretation, writing and critical review of its intellectual content; FNA: data analysis and interpretation, writing and critical review of its intellectual content; CPM: data analysis and interpretation, writing and critical review of its intellectual content; SGO: data collection, analysis and interpretation, and critical review of its intellectual content; GDBA: substantial contribution to the work in its conception and design, data collection, analysis and interpretation, writing and critical review of its intellectual content.

REFERENCES

1. Arden N, Nevitt MC. Osteoarthritis: epidemiology. Best Pract Res Clin Rheumatol. 2006;20(1):3-25.
2. Aggarwal AK, Singh N, Sudesh P. Topical vs Intravenous Tranexamic Acid in Reducing Blood Loss After Bilateral Total Knee Arthroplasty: A Prospective Study. J Arthroplasty. 2016;31(7):1442-8.
3. Kim RH, Springer BD, Douglas DA. Knee reconstruction and replacement. In: Flynn F, editor. Orthopaedic knowledge update. Rosemont, IL: American Academy of Orthopaedic Surgeons; 2011. p. 469-75.
4. Sehat KR, Evans RL, Newman JH. Hidden blood loss following hip and knee arthroplasty. Correct management of blood loss should take hidden loss into account. J Bone Joint Surg Br. 2004;86(4):561-5.
5. Good L, Peterson E, Lisander B. Tranexamic acid decreases external blood loss but not hidden blood loss in total knee replacement. Brit J Anaesth. 2003;90(5):596-9.
6. Henry DA, Carless PA, Moxey AJ, O'Connell D, Stokes BJ, Fergusson DA, Ker K. Antifibrinolytic use for minimizing perioperative allogeneic blood transfusion. Cochrane Database Syst Rev. 2011;(1):CD001886.
7. Coetzee MJ. The use of topical crushed tranexamic acid tablets to control bleeding after dental surgery and from skin ulcers in haemophilia. Haemophilia. 2007;13(4):443-4.
8. Wong J, Abrishami A, El Beheiry H, Mahomed NN, Davey JR, Gandhi R, et al. Topical application of tranexamic acid reduces postoperative blood loss in total knee arthroplasty a randomized, controlled trial. J Bone Joint Surg Am. 2010; 92(15):2503-13.
9. CRASH-2 trial collaborators. Effects of tranexamic acid on death, vascular occlusive events, and blood transfusion in trauma patients with significant haemorrhage (CRASH-2): a randomized, placebo-controlled trial. Lancet. 2010;376(9734):23-32.
10. Jixiang T, Hong C, Qin L, Cheng C, Wei H. A meta-analysis of the effectiveness and safety of using tranexamic acid in primary unilateral total knee arthroplasty. J Surg Res. 2013;184(2):880-7.
11. Altman R, Asch E, Bloch D, Bole G, Borenstein D, Brandt K, et al. Development of criteria for the classification and reporting of osteoarthritis. Classification of osteoarthritis of knee. Arthritis Rheum. 1986;29(8):1039-49.
12. Kellgren JH, Lawrence JS. Radiological assessment of osteo-arthrosis. Ann Rheum Dis. 1957;16(4):494-502.
13. Bidolegui F, Arce G, Lugones A, Pereira S, Vindver G. Tranexamic Acid Reduces Blood Loss and Transfusion in Patients Undergoing Total Knee Arthroplasty without Tourniquet: A Prospective Randomized Controlled Trial. Open Orthop J. 2014;8:250-54.
14. Lima ALLM, Pécora JR, Albuquerque RM, Paula AP, D'Élia CO, Santos ALG, Croci AT. Infecção pós-artroplastia total do joelho: considerações e protocolo de tratamento. Acta Ortop Bras. 2004;12(4):236-41.
15. Ejaz A, Laursen AC, Kappel A, Laursen MB, Jakobsen T, Rasmussen S, Nielsen PT. Faster recovery without the use of a tourniquet in total knee arthroplasty. Acta Orthop. 2014;85(4):422-6.
16. Tsumara N, Yoshiya S, Chin T, Shiba R, Kohso K, Doita M. A prospective comparison of clamping the drain or post-operative salvage of blood in reducing blood loss after total knee arthroplasty. J Bone Joint Surg Br. 2006;88(1):49-53.
17. 1Leão MGS, Souza HAP, Ferreira YMC. Avaliação da perda sanguínea após a liberação precoce ou tardia da isquemia em pacientes submetidos à artroplastia total do joelho. Rev Bras Ortop. 2013;48(2):152-8.
18. Zekcer A, Del Priori R, Tieppo C, Silva RS, Severino NR. Estudo comparativo com uso do ácido tranexâmico tópico e intravenoso em relação à perda sanguínea na artroplastia total do joelho. Rev Bras Ortop. 2017;52(5):589-95.
19. Andrade MAP, Campos TVO, Silva BFA, Assis ME, Boechat LC, Biondi LF, et al. Avaliação prospectiva dos pacientes submetidos à artroplastia total do joelho com e sem colocação de dreno de sucção. Rev Bras Ortop. 2010;45(6):549-53.
20. Esler CNA, Blakeway C, Fiddian NJ. The use of a closed-suction drain in total knee arthroplasty. A prospective randomised study. J Bone Joint Surg Br. 2003;85(2):215-7.

DOI: http://dx.doi.org/10.1590/1413-785220212904240251

IS THE "U-SIGN" RADIOLOGIC FEATURE OF A POSTERIOR CRUCIATE LIGAMENT TIBIAL AVULSION FRACTURE?

A IMAGEM DO "U-RADIOLÓGICO" É UM SINAL DA FRATURA-AVULSÃO TIBIAL LIGAMENTO CRUZADO POSTERIOR?

Sergio Rocha Piedade[1], *Daniel Miranda Ferreira*[1], *Mark Hutchinson*[2], *Nicola Maffulli*[3], *Martha Maria Mischan*[4], *Philippe Neyret*[5]

1. Universidade Estadual de Campinas, Faculdade de Ciências Médicas, Campinas, SP, Brazil.
2. University of Illinois at Chicago, Chicago, IL, USA.
3. Centre for Sports and Exercise Medicine, Barts and The London School of Medicine and Dentistry, Mile End Hospital, London, UK.
4. Universidade Estadual Paulista, Instituto de Biociências, Departamento de Bioestatística, Botucatu, SP, Brazil.
5. University of Lyon, Lyon, France.

ABSTRACT

Objective: By analyzing our cases of posterior cruciate ligament (PCL) tibial avulsion fracture, we noted that a U-shaped image was present in the anteroposterior plain radiographs view of the affected knee, even in cases where the profile view of the knee had been inconclusive as to tibial PCL avulsion fracture, a "hidden" fracture. Therefore, we aimed to investigate whether there was an anatomical correlation between this radiological U sign and the tibial insertion of the PCL and to ascertain the intra- and inter-rater reliability of this sign in clinical practice. Methods: The data of the widths and heights area of the PCL tibial insertion area, and the U sign area were measured and compared to the largest width of the tibia. Two moreover, the reliability and reproducibility of this imaging were analyzed. Results: The areas height of the U-sign area and the anatomical insertion area of the posterior cruciate ligament showed no difference, and both were topographically located in the two central quarters of the proximal end of the tibia. The radiographic assessment showed excellent Kappa agreement rates between interobserver and intraobserver, with high reliability and reproducibility. Conclusion: The U sign is a radiographic feature of PCL tibial avulsion fracture seen on the radiograph AP view, there is a high association between the ratios of the U-sign area height in the X-ray and the anatomical height of the PCL tibial insertion site MRI with the largest width of the proximal tibia. The radiographic U sign showed excellent rates of interobserver and intraobserver agreement with Kappa values higher than 0.8. ***Level of Evidence IV; Dignostic Studies – Investigating a Diagnostic Test.***

Keywords: Posterior Cruciate Ligament. Fractures Avulsion; Knee; Radiography; Diagnosis.

RESUMO

Objetivo: Avaliando nossos casos de fratura-avulsão da inserção tibial do ligamento cruzado posterior, observamos que uma imagem em forma de U estava presente na radiografia plana anteroposterior do joelho afetado, mesmo nos casos em que a visão do perfil do joelho era inconclusiva quanto à fratura por avulsão do ligamento cruzado posterior (LCP) tibial, uma fratura "oculta". Portanto, buscamos investigar se havia uma correlação anatômica entre esse sinal radiológico U e a inserção tibial do LCP, além de verificar a confiabilidade intra e interexaminadores desse sinal na prática clínica. Métodos: Os dados das larguras e alturas da área de inserção tibial do LCP e da área do sinal U foram medidos e comparados com a maior largura da tíbia. Além disso, foram analisadas a confiabilidade e a reprodutibilidade dessa imagem. Resultados: A altura da área do sinal U e da área de inserção anatômica do ligamento cruzado posterior não mostraram diferença, e ambas estavam localizadas topograficamente nos dois quartos centrais da extremidade proximal da tíbia. A avaliação radiográfica mostrou excelentes taxas de concordância Kappa entre interobservador e intraobservador, com alta confiabilidade e reprodutibilidade. Conclusão: O sinal U é uma característica radiográfica da fratura por avulsão tibial do LCP que pode vista na radiografia AP. Existe uma alta associação entre as proporções da altura da área do sinal U na radiografia e da altura anatômica da inserção tibial do LCP RM local em relação à maior largura da tíbia proximal. O sinal radiográfico U mostrou excelentes taxas de concordância interobservador e intraobservador, com valores de Kappa superiores a 0,8. ***Nível de Evidência IV, Estudos Diagnósticos – Investigação de um exame para diagnóstico.***

Descritores: *Ligamento Cruzado Posterior; Fratura Avulsão; Joelho; Radiografia; Diagnóstico.*

Citation: Piedade SR, Ferreira DM, Hutchinson M, Maffulli N, Mischan MM, Neyret P. Is the "U-sign" radiologic feature of a posterior cruciate ligament tibial avulsion fracture? Acta Ortop Bras. [online]. 2021;29(4):189-192. Available from URL: http://www.scielo.br/aob.

All authors declare no potential conflict of interest related to this article.

The study was conducted at the **Department of Orthopedic and Traumatology, School of Medical Science, University of Campinas.**
Correspondence: Sergio Rocha Piedade. Rua Severo Penteado 131, apto 1, Campinas, SP, Brazil, 13025050. piedade@unicamp.br

Article received on 07/26/2020, approved on 09/24/2020.

INTRODUCTION

The knee joint is a complex hinge joint that depends not only the structure of the bone but also the collateral and cructiate ligaments to maintain stability and structure. Physical and athletic demands such as running, jumping, acceleration/deceleration, changing direction, and absorbing forces are done with the knee at a certain degree of flexion which in turn exposes the ligaments to greater loads making them more vulnerable to injury.[1] The posterior cruciate ligament (PCL) is the primary stabilizer to posterior tibial translation and a secondary stabilizer versus rotation.

Avulsion fractures of the posterior cruciate ligament at its tibial insertion are one of the most common forms of isolated PCL injury,[1-3] usually resulting from low energy trauma.[4-7] At presentation, plain radiography is the first imaging exam performed, and generally plain radiographs of the knee are sufficient to diagnose avulsion fractures of the posterior cruciate ligament. Indeed, on lateral knee radiographs, avulsion of the tibial insertion of the posterior cruciate ligament appears as focal interruption of the posterior surface of the tibia.[8]

However, since PCL tibial avulsion is uncommon in clinical practice, some surgeons may not identify this injury on radiographs,[9] for example when the avulsed bone may be hidden in the lateral view or appears anteriorly to its original anatomic position in lateral radiographic view of the knee. Henry Dejour,[10] the French orthopedist, in a personal communication, suggested that avulsion fractures of the posterior cruciate ligament at its tibial insertion presented a U-shaped image on plain anteroposterior radiographs. The tibial insertion of the PCL is anatomically complex, but its shape and position seem to be consistent.[11] The relationship between the U sign and the tibial insertion of the PCL has not been systematically investigated. In clinical practice, we noted that our patients with a PCL avulsion fracture at the tibial insertion presented a U-shaped radiographic image in the anteroposterior view of the knee, even in cases in which the radiograph in the lateral view of the knee PCL had been inconclusive or unclear as to tibial avulsion fracture, a "hidden" fracture (Figure 1A, B and C). We therefore aimed to establish whether it was possible to use this radiographic sign in clinical practice.

MATERIALS AND METHODS

From January 1997 to December 2005, 21 consecutive patients underwent surgical treatment for PCL avulsion at the tibial insertion site by the same surgeon. We had preoperative radiographs 19 out of these 21 patients, which constituted our study group. A control group was produced after evaluating 63 MRI scans of patients that did not present, as a final imaging diagnosis, bone or soft tissue lesions of the knee. Based on magnetic resonance scans (Figure 2A, B, C) and anteroposterior radiographs of the knee (Figure 3), the width and height of the PCL tibial insertion area and the U sign area at the avulsed tibial fracture site were measured, respectively, and expressed as a ratio of the largest width of the proximal tibia. This research work was approved by the University Ethics Committee, and an informed consent was obtained from the participants of this research and registered under the study number CAAE 32856620.0.0000.5404.

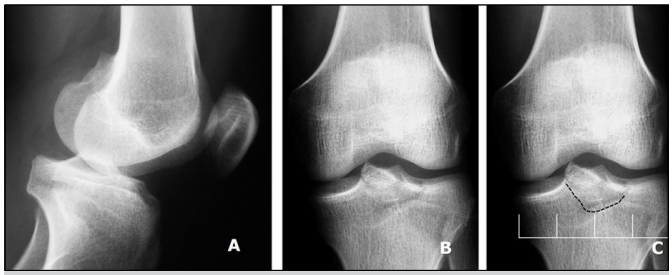

Figure 1. A "hidden" avulsion fracture of the posterior cruciate ligament of the left knee on the lateral view (Figure 1A) and the presence of the radiologic U-sign (Figure 1B and 1C-dotted line) in the anteroposterior X-ray.

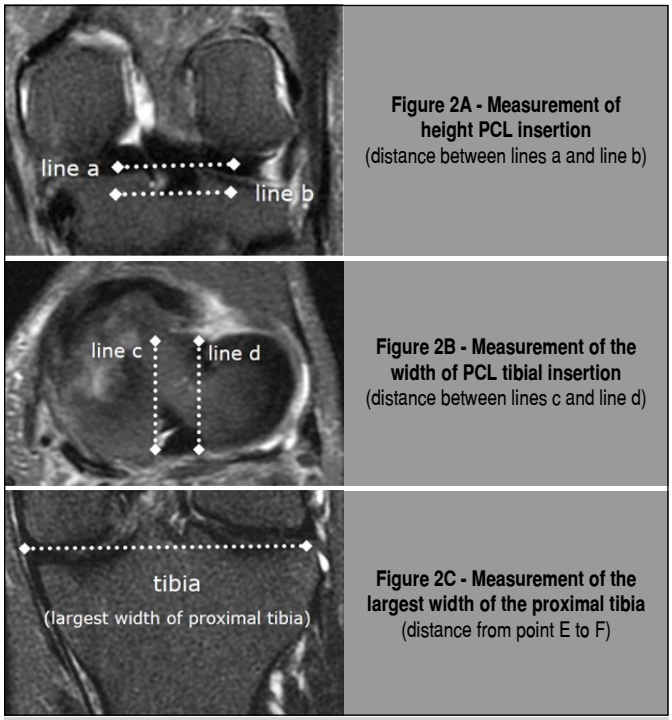

Figure 2A - Measurement of height PCL insertion
(distance between lines a and line b)

Figure 2B - Measurement of the width of PCL tibial insertion
(distance between lines c and line d)

Figure 2C - Measurement of the largest width of the proximal tibia
(distance from point E to F)

Figure 2. Measurements of height (2A), width (2B), and the largest width of the tibia (2C) performed on MRI scan.

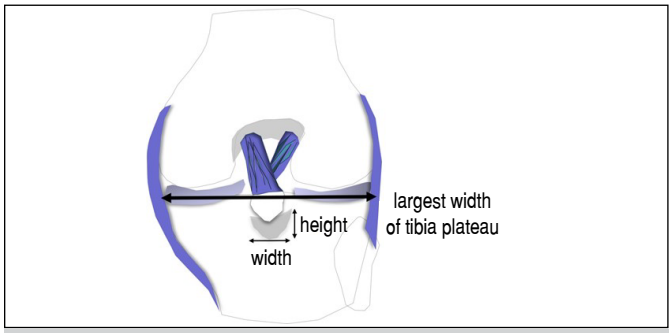

Figure 3. Scheme of measurement of width and height of the U-shaped radiological image and proximal tibial axis (radiological U-sign).

Analysis of interrater reliability of radiological U-sign

Two fellowship-trained musculoskeletal radiologists were invited to evaluate the presence of the U-shaped radiological image (radiological U sign) in 36 anteroposterior radiographs views of the knee joint. Radiographs consisted of cases of PCL tibial avulsion fracture (50%) and no bone injury (50%). Results obtained were compared with the final surgical findings. The Kappa statistics was used to obtain inter-observer and intra-observer agreement of two expert radiologists. Interpretation of the agreement values was based on the method proposed by Landis and Koch.[12]

Statistical analysis

Based on the results, the analysis of variance was used to investigate the influence of the distribution of the data obtained in PCL tibial avulsion fracture group ($n = 19$) and MRI scan group (control group) ($n = 63$). The significance was set at $p < 0.05$, and the data obtained from the two groups were tabulated (Table 1 and 2).

RESULTS

The descriptive characteristics of the two groups under exam are given in Tables 1 and 2.

Table 1. Descriptive analysis of PCL tibial avulsion fracture group.

	n	mean	std dev	sum	minimum	maximum
tibia (proximal axis)	19	50.28	14.98	955.34	31.60	93.21
U height	19	7.82	2.52	148.62	5.11	14.04
U width	19	19.34	6.39	367.47	10.85	36.00
Y1 (U width / tíbial axis)	19	38.91	8.44	739.22	20.61	54.85
Y2 (U heigth / tíbial axis)	19	15.64	2.32	297.21	11.54	19.91
Y3 (area)	19	161.88	105.35	3076.00	58.71	505.44
Y3*	19	2.22	0.13	42.15	2.02	2.50
Y4 (U width / U height)	19	2.52	0.57	47.83	1.55	3.87

* variable transformed to logarithms, aiming to homogenize the variances.

Table 2. Descriptive analysis of MRI Group (control group).

	n	mean	std dev	sum	minimum	maximum
tibia (proximal axis)	63	7.52	0.66	474.09	5.40	8.70
height (PCL tibia insertion height)	63	1.19	0.22	75.08	0.70	1.73
width (PCL tibia insertion width)	63	1.44	0.25	90.97	0.90	2.00
Y1 (U width / tíbial axis)	63	19.24	3.17	1212.00	11.11	27.12
Y2 (U heigth / tíbial axis)	63	15.93	3.28	1004.00	8.97	31.48
Y3 (area)	63	1.72	0.43	108.25	0.98	2.89
Y3*	63	0.99	0.079	62.43	0.83	1.17
Y4 (U width / U height)	63	1.25	0.33	79.04	0.60	2.00

* variable transformed to logarithms, aiming to homogenize the variances.

On both plain radiographs and MRI, the radiological U sign and the PCL tibial insertion site were in the two central quarters of the proximal tibia (Figure 1C). There were no statistically significant differences between the mean height values of the tibial insertion area and that of the U sign with the largest width of the proximal tibia ($p = 0.72$). However, the analysis revealed a statistical difference between the mean width values to the largest transverse width of the proximal tibia ($p < 0.0001$) (Table 3 and 4).

Table 3. Analysis of variance, F test and p-value of measures Y1, Y2, Y3 and Y4 obtained in both study groups.

Measures	F test	P value	Variance
Y1	237.08	< 0.0001	20.5
Y2	0.13	0.72	19.5
Y3*	2648.21	< 0.0001	7.1
Y4	147.45	< 0.0001	25.7

Y1: U width/tibia; Y2: U height/tibia); Y3: area; Y4: U width/U height.
* Variables transformed into logarithms, aimed at homogenizing the variances.

Table 4. Comparative analysis between means of measures Y1, Y2, Y3 and Y4 obtained in both study groups.

Groups	Y1	Y2	Y3	Y4
PCL avulsion fracture	38.91a	15.64a	161.88a	2.52a
MRI scan	19.24b	15.93a	1.72b	1.26b

Y1: U width/tibia; Y2: U height/tibia; Y3: área; Y4: U width/U height.
* means followed by the same letter do not differ at 5%.

The Kappa coefficient results presented excellent agreement in inter-observer and intra-observer analysis (Table 5 and 6).

Table 5. Kappa coefficients for the first and the second intra-observer evaluation compare to final surgical findings.

intra-observers	Kappa index	confidence interval	p-value	agreement
1	0.925	1.0-0.737	< 0.001	excellent
2	0.851	1.0-0.662	< 0.001	excellent

Table 6. Kappa coefficients for the first and the second evaluation compare to final surgical findings.

interobserver	Kappa index	confidence interval	p value	agreement
first evaluation	0.889	1.0-0.7	< 0.001	excellent
second evaluation	0.888	1.0-0.7	< 0.001	excellent

DISCUSSION

The most important findings of this study are that the U sign is a radiographic feature of the area of PCL tibial avulsion fracture seen on the radiograph AP view. There is a high association between the ratios of the U-sign height area in the X-ray and the anatomical height of the PCL tibial insertion site MRI with the largest width of the proximal tibia. Moreover, their topography is consistently situated in the two central quarters of the proximal tibia (Figure 2C). Moreover, this radiographic sign exhibits intra and inter-observer characteristics, with excellent agreement rates between inter and intra-observer analysis with Kappa values higher than 0.8, confirming its high reproducibility and applicability.

Tibial avulsion fracture of the PCL are uncommon,[13] and precise diagnosis is necessary to define the optimal treatment for each specific patient.

The posterior surface of the tibia has a unique tridimensional anatomy, to which several structures converge, including the tibial plateau, the posterior intercondylar fossa, and the posterior cortex. The posterior cruciate ligament inserts into a central inclined depression between the medial and lateral parts of the tibial plateau, distinct from the vertical cortex of the tibia.[13]

A tomography with three-dimensional reconstruction provides great details on the size of the bone fragment, its displacement, and presence of comminution, helping to better plan the therapeutic approach.[14] However, it involves ionizing radiations, and in this respect it is more invasive than plain radiography.

When bone avulsion of the posterior cruciate ligament at its tibial insertion is associated with fragment displacement, surgery should be planned, since it generally produces better results than conservative management.[2,15-17]

To our knowledge, the literature has not yet investigated a correlation between the dimensions of the tibial insertion of the PCL with the radiographic features of tibial avulsion fractures on the anteroposterior radiographs of the knee. Therefore, the U sign can alert physicians to the presence of the injury even when a "hidden" PCL tibial avulsion fracture is not visualized in lateral radiographic views (Figure 1A). Moreover, when the avulsed bone appears anteriorly to its original anatomic position in the lateral radiographic view of the knee, the orthopedist might inaccurately diagnose it as a fracture of the tibial plateau or a bone avulsion of the anterior cruciate ligament.[18,19] In this context, the U sign seems to offer valuable information to supplement the clinical and imaging diagnosis of PCL avulsion fractures.

CONCLUSION

The U sign is a radiographic feature of PCL tibial avulsion fracture seen on the radiograph AP view. There is a high association between the ratios of the U-sign height in the X-ray, and the anatomical height of the PCL tibial insertion site MRI with the largest width of the proximal tibia. The radiographic U sign showed excellent rates of interobserver and intraobserver agreement with Kappa values higher than 0.8.

AUTHORS' CONTRIBUTIONS: Each author contributed individually and significantly to the development of this article. SRP: substantial contribution to the study in its conception, design, data collection, analysis and interpretation of data, writing and critical review of its intellectual content, and approval of the final version of the manuscript to be published; DMF: data collection, analysis and interpretation, writing and critical review of its intellectual content, and approval of the final version of the manuscript to be published; MH: writing and critical review of its intellectual contentand approval of the final version of the manuscript to be published; NM: final approval of the version of the manuscript to be published; MMM: analysis, data interpretation and final approval of the manuscript version to be published; PN: writing and critical review of its intellectual content, and approval of the final version of the manuscript to be published.

REFERENCES

1. Flandry F, Hommel G. Normal anatomy and biomechanics of the knee. Sports Med Arthrosc Rev. 2011;19(2):82-92.
2. Bonin N, Jeunet L, Obert L, Dejour D. Adult tibial eminence fracture fixation: arthroscopic procedure using K-wire folded fixation. Knee Surg Sports Traumatol Arthrosc. 2007;15(7):857-62.
3. Katsman A, Strauss EJ, Campbell KA, Alaia MJ. Posterior cruciate ligament avulsion fractures. Curr Rev Musculoskelet Med. 2018;11(3):503-9.
4. Hesse E, Bastian L, Zeichen J, Pertschy S, Bosch U, Krettek C. Femoral avulsion fracture of the posterior cruciate ligament in association with a rupture of the popliteal artery in a 9-year-old boy: a case report. Knee Surg Sports Traumatol Arthrosc. 2006;14(4):335-9.
5. Clanton TO, Delee JC, Sanders B, Neidre A. Knee ligament injuries in children. J Bone Joint Surg Am. 1979;61(8):1195-201.
6. Al-Ahaideb A. Posterior cruciate ligament avulsion fracture in children: a case report with long-term follow-up and comprehensive literature review. Eur J Orthop Surg Traumatol. 2013;23 (Suppl 2):S257-60.
7. Piedade SR, Mischan MM. Surgical treatment of avulsion fracture of the knee PCL tibial insertion: experience with 21 cases. Acta Ortop Bras. 2007;15(5):272-5.
8. Hoogervorst P, Gardeniers Jwm, Moret-Wever S, Van Kampen A. Pseudo-arthrosis repair of a posterior cruciate ligament. Knee Surg Sports Traumatol Arthrosc. 2010;18(11):1612-6.
9. Meyers MH. Isolated avulsion of the tibial attachment of the posterior cruciate ligament of the knee. J Bone Joint Surg Am. 1975;57(5):669-72.
10. Dejour H. Lesões ligamentares do joelho. Proceedings of the 3rd Jornada Catarinense de Fisioterapia Ortopedica e Traumatologica; 1998 May 27-30; Joinvile, SC.
11. Tajima G, Nozaki M, Iriuchishima T, Ingham SJ, Shen W, Smolinski P, Fu FH. Morphology of the tibial insertion of the posterior cruciate ligament. J Bone Joint Surg Am. 2009;91(4):859-66.
12. Landis JR, Koch GG. The measurement of observer agreement for categorical data. Biometrics. 1977;33(1):159-74.
13. Moorman CT 3rd, Zane MSM, Bansai S, Cina SJ, Wickiewicz TL, Warren RF, Kaseta MK. Tibial insertion of the posterior cruciate ligament: a sagital plane analysis using gross, histologic, and radiographic methods. Arthroscopy. 2008;24(3):269-75.
14. Nikiforidis P, Babis G, Kateros K, Vlamis J, Korres DS. Isolated avulsion fracture of the tibial attachment of the posterior cruciate ligament. Eur J Orthop Surg Traumatol. 2000;10(4):257-59.
15. Deehan DJ, Pinczewski LA. Arthroscopic reattachment of an avulsion fracture of the tibial insertion of the posterior cruciate ligament. Arthroscopy. 2001;17(4):422-5.
16. Horas U, Meissner SA, Heiss C, Schnettler R. Arthroscopic fixation of posterior cruciate ligament avulsion fractures: a new minimally invasive technique. Knee Surg Sports Traumatol Arthrosc. 2010;18(6):781-3.
17. Joshi S, Bhatia C, Gondane A, Rai A, Singh S, Gupta S. Open reduction and internal fixation of isolated posterior cruciate ligament avulsion fractures: clinical and functional outcome. Knee Surg Relat Res. 2017;29(3):210-6.
18. Griffith JF, Antonio GE, Tong CW, Ming CK. Cruciate ligament avulsion fractures. Arthroscopy. 2004;20(8):803-12.
19. Nizlan MN, Suhail A, Samsudin OC, Masbah O. An unusual radiographic presentation of posterior cruciate ligament avulsion fracture. Med J Malaysia. 2004;59(Suppl F):65-8.

DOI: http://dx.doi.org/10.1590/1413-785220212904240552

MORTALITY DUE TO TRANSPORT ACCIDENTS IN THE CITY OF SÃO PAULO: 2005-2015

MORTALIDADE POR ACIDENTES DE TRANSPORTE NO MUNICÍPIO DE SÃO PAULO: 2005-2015

Fábio Boucault Tranchitella[1], Renata Souza dos Santos[1], Jamili Jamel Sakr Hussein El Bacha[1], Júlia Villibor Sobrado[1], Matheus Bortoloci Sampaio dos Santos[1], Patrícia Colombo Souza[1]

1. Universidade Santo Amaro, São Paulo, SP, Brasil.

ABSTRACT

Objective: To characterize cases of land transport accidents in the macro-regions of city of São Paulo in 2005, 2010, and 2015. Methods: This is a population-based, longitudinal and retrospective study of time series, based on a quantitative survey of land transport accidents that occurred in the city of São Paulo in 2005, 2010 and 2015 using data from the Mortality Information System of the City of São Paulo. Results: A total of 1,343, 1,567 and 1,088 deaths by accident recorded in the city' population in the years 2005, 2010 and 2015 respectively. The highest occurrences were in the age groups 15 to 24 years and 24 to 34 years. The highest number of deaths due to accidents was among males. The mortality rates observed in the macro-regions were South (23.8%), East (22%), North (21.6%), West (7.1%), and Center (3%). In comparing the years examined, there was a decline in the mortality rate per 100,000 inhabitants in most macro-regions. Conclusion: Despite the decrease in overall accident mortality in most macro-regions, it still deserves attention on preventive traffic actions focused on young males living in peripheral neighborhoods, since they represent the most susceptible group. ***Level of evidence II; Retrospective Study.***

Keywords: Accidents, Traffic. Mortality. Accident Prevention.

RESUMO

Objetivo: Caracterizar os casos de acidentes de transporte terrestre nas macrorregiões do município de São Paulo nos anos de 2005, 2010 e 2015. Métodos: Trata-se de estudo de base populacional, longitudinal e retrospectivo de séries temporais, embasado em um levantamento quantitativo dos acidentes de transporte terrestres ocorridos no município de São Paulo nos anos de 2005, 2010 e 2015, utilizando dados provenientes do Sistema de Informações sobre Mortalidade. Resultados: Um total de 1.343, 1.567 e 1.088 óbitos por acidente foram registrados para a população do município nos anos de 2005, 2010 e 2015, respectivamente. A maior ocorrência se deu nas faixas etárias de 15 a 24 anos e 24 a 34 anos. O maior número de mortes por acidentes se deu no sexo masculino. As taxas de mortalidade observadas nas macrorregiões foram: Sul (23,8%), Leste (22%), Norte (21,6%), Oeste (7,1%) e Centro (3%). Comparando-se períodos, houve queda nos coeficientes padronizados de mortalidade geral por 100 mil habitantes na maioria das macrorregiões. Conclusão: Apesar da queda na mortalidade geral dos acidentes na maioria das macrorregiões, ela ainda merece atenção e foco em ações de trânsito preventivas direcionadas aos jovens do sexo masculino que residem em bairros periféricos, pois representam o grupo mais suscetível. Nível II – Estudo prognóstico – Investigação do efeito de características de um paciente sobre o desfecho da doença. ***Nível de Evidência II; Estudo retrospectivo.***

Descritores: *Acidentes de Trânsito. Mortalidade. Prevenção de Acidentes.*

Citation: Tranchitella FB, Santos RS, El Bacha JJSH, Sobrado JV, Santos MBS, Colombo-Souza P. Mortality for transport accidents in the municipality of São Paulo: 2005-2015. Acta Ortop Bras. [online]. 2021;29(4):193-196. Available from URL: http://www.scielo.br/aob.

INTRODUCTION

Traffic accidents represent a serious global public health problem. The World Health Organization (WHO) estimates that the annual number of deaths from land transport accidents (LTA) is 1.24 million people, mostly from middle-income countries.[1] It is estimated that if no action is taken to reverse this scenario, by 2020 traffic deaths could reach 1.9 million people worldwide and become the 5th leading cause of death in 2030.[2,3]

Worldwide, 77% of traffic deaths occur among the young male population. Accidents represent the leading cause of death among men aged 15 to 29 years; and the 3rd cause among those aged 30 to 49 years.[1] Regarding the victim category, occupants of motor vehicles, followed by pedestrians and motorcyclists are at the most risk, accounting for 36%, 35%, and 16% respectively of all traffic deaths.[2,4]

In Brazil, from 1996 to 2015, 21,057,086 people died, of which 2,656,875 were due to External Causes (12.6%). Among the external

All authors declare no potential conflict of interest related to this article.

The study was conducted at Universidade Santo Amaro, SP, Brasil.
Correspondence: Patrícia Colombo de Souza. Rua Prof. Enéas de Siqueira Neto 340, São Paulo, SP, Brasil. 04829300. e-mail: pcolombo@prof.unisa.br

Artigo recebido em 06/07/2020, aprovado em 24/09/2020.

causes, LTA appear as the second most prevalent cause, being responsible for the deaths of 733,120 people (27.6% of deaths by cause and 3.5% of total deaths in the period).[5]

Traffic accidents have a significant impact on the country's economy, not only due to the high costs of care and hospitalization of victims, but also because it is responsible for the death of a significant portion of the economically active population.[6] Several factors may contribute to the occurrence of these accidents, such as inadequate enforcement of traffic laws, the increase in the vehicle fleet, and the consumption of alcoholic beverages. In addition, the association between alcohol consumption and non-use of safety equipment has been appointed as more prevalent among men from 22 to 45 years old.[7,8]

The damage to health resulting from these accidents can reach various dimensions, resulting in physical and emotional repercussions that reduce the quality of life at both individual and collective levels and generate an overload on health services. External causes demand more complex hospital procedures, such as higher number of surgeries, the need for intensive care, drug consumption, and multidisciplinary support, bringing higher costs to health services.[4]

Considering these perspectives and the importance of LTA for the occurrence of deaths, the aim of this study was to characterize the cases of LTA in the macro-regions of the city of São Paulo in the years 2005, 2010, and 2015.

METHOD

This is a population-based, longitudinal and retrospective study of time series, based on a quantitative survey of LTAs that occurred in the city of São Paulo in 2005, 2010 and 2015. We used data from the Mortality Information System of the City of São Paulo, which processed the declarations of deaths that occurred in the city, using as a base document the Death certificate (DC), completed and signed by a physician. LTA were considered to be pedestrian and cyclist collisions; trauma in accidents involving motorcyclists and the remaining transport accidents.[9]

Due to the probable changes that occurred in each of the populations in the time elapsed between 2000 and 2015, we proposed the calculation of the standard median population for each year of information collection.

In comparing populations, the mortality coefficient was standardized to correct distortions resulting from possible differences in its composition linked to attributes or variables that are related to the probability of death.[10]

We selected all deaths related to LTA in the population residing in the city of São Paulo and stratified them by sex (male or female), age group (WHO criterion, every 5 years), macro-regions of the city (south, southeast, east, center, west and north) and years of occurrence (2005, 2010 and 2015).

The choice of the median of the percentages of participation, instead of the arithmetic mean, aimed to remove the bias that the latter could bring due to the possible occurrence, in certain populations, of percentages of participation that strongly differ from the others. Considering this alteration, all regions had their coefficient of occurrence standardized, following the constitution of the median standard population.[11] Since we have six regions, the median was represented by the average of the populations situated in the 3rd and 4th positions of the order of populations in ascending order. The median was calculated for each of the years considered in the study (Table 1).

Table 1. Regions of the City of São Paulo according to the median population and respective positions (P) in ascending order in the years 2005, 2010 and 2015.

Region	P	2005	P	2010	P	2015
South	**4**	2,408,507	5	2,551,020	5	2,684,981
East	5	2,326,697	**4**	2,379,685	**4**	2,441,615
Southeast	6	2,596,056	6	2,648,640	6	2,686,027
West	2	973,558	2	1,022,564	2	1,055,106
Center	1	403,220	1	430,599	1	448,565
North	**3**	2,158,535	**3**	2,213,477	**3**	2,265,504
Median pop.		**2,242,616**		**2,296,581**		**2,353,559**

Once the median populations were established the value of the standardized coefficient (PC%) of occurrence corresponding to the ATTs was calculated, for each year, following the standard population, using the expression: number of events x 100,000 inhabitants/standard median population.

For the analysis of the results, we applied the Chi-square test to compare the regions of the city in relation to the percentage of LTA for the years 2005, 2010, and 2015. The significance level was established at 0.05.

RESULTS

A total of 1,343, 1,567 and 1088 deaths from LTA were registered for the population of the city of São Paulo in the years 2005, 2010 and 2015, respectively.

According to Table 2, the age groups between 15 to 24 years and 24 to 34 years presented the highest number of occurrences, totaling 43.4% of the cases, followed by the age group 35 to 44 years with 15% of the records and 45 to 54 years with an average of 12%. Age groups above and below these marks presented less than 10% of the cases. We also verified males presented the highest number of deaths by accidents on average in the 3 years examined, corresponding to 78.9% of the cases, against only 21.1% of the deaths of females.

Table 2. Sociodemographic characterization of those involved in LTA that occurred in the regions of the municipality of São Paulo in the years 2005, 2010 and 2015.

Sociodemographic data	2005		2010		2015	
Age group	**N**	**%**	**N**	**%**	**N**	**%**
< 1	2	0.18	3	0.2	1	0.09
1 to 4	15	1,2	6	0.4	9	0.8
5 to 14	53	4.0	45	2.9	28	2.6
15 to 24	318	23.9	337	22.0	250	23.0
25 to 34	267	20.1	346	22.5	201	18.5
35 to 44	203	15.3	229	14.9	167	15.4
45 to 54	169	12.7	204	13.3	120	11.0
55 to 64	86	6.5	127	8.2	128	11.8
65 to 74	110	8.2	112	7.3	92	8.4
75 and +	105	7.9	128	8.3	91	8.4
TOTAL	**1,328***	**100.0**	**1,537****	**100.0**	**1,087*****	**100.0**
Gender	**N**	**%**	**N**	**%**	**N**	**%**
Female	297	22.2	302	19.3	236	21.7
Male	1046	77.8	1265	80.7	852	78.3
TOTAL	**1,343**	**100.0**	**1,567**	**100.0**	**1,088**	**100.0**
REGION	**N**	**%**	**N**	**%**	**N**	**%**
Center	29	2.3	50	3.4	35	3.2
West	281	22.4	314	22.1	263	24.2

Table 2. Sociodemographic characterization of those involved in LTA that occurred in the regions of the municipality of São Paulo in the years 2005, 2010 and 2015.

Sociodemographic data	2005		2010		2015	
North	277	22.1	304	21.3	234	21.5
West	76	6.0	91	6.4	97	8.9
Southeast	290	21.1	321	22.5	210	19.3
South	302	24.1	347	24.3	249	22.9
TOTAL	**1,255'**	**100.0**	**1,427''**	**100.0**	**1,088**	**100.0**

*15 without age information; **30 without age information; ***1 without age information; '88 without region information; "140 without region information

Table 2 also identifies the transportation accidents that occurred in the municipality of São Paulo by macro-regions in the years 2005, 2010, and 2015. The highest LTA fatalities were observed in the south (23.8%), east (22%), north (21.6%), and southeast (21%) regions. The lowest mortalities occurred in the west (7.1%) and center (3%) regions.

The results presented in Table 3 show a significant decrease in the standardized coefficients of general mortality from LTA per 100,000 inhabitants in most of the regions studied, in comparing the three periods examined.

Table 3. Standardized Coefficients (SC)% per 100,000 inhabitants of Traffic Accidents, occurring by regions of the Municipality of São Paulo, estimated for the median standard populations for each year. Result of the chi-square test, applied to compare the regions.

Region	Year			SC (%) Mean	Chi-Square Test
	2005	2010	2015		
South	13.5	15.1	10.6	13.1	X2 = 17.88 (p=0.0005)*
Southeast	12.9	10.3	8.9	10.7	X2 = 13.29 (p=0.0040)*
North	12.4	13.2	9.9	11.8	X2 = 3.26 (p = 0.5153)
West	3.4	4.0	4.1	3.8	X2 = 2.83 (p = 0.5870)
Central	1.3	2.2	1.2	1.6	X2 = 5.92 (p = 0.1156)
East	12.5	13.7	8.7	11.6	X2 = 14.25 (p = 0.0025)*

The southeast (12.9 – 8.9) and east (12.5 – 8.7) regions presented the greatest decrease in coefficients, showing a statistically significant reduction of 31.3% (p = 0.0040) and 30.4% (p = 0.0025) respectively, followed by the south region, with an also significant decrease of 21.8% (13.5 – 10.6) (p = 0.0005). The reduction also happened in the north (12.4 – 9.9) and center (1.3 – 1.2) regions – 20.2% and 7.7% respectively – but were not considered representative or statistically significant. And in the west region (3.4 – 4.1) there was an increase of 20.5%, considered not statistically significant too.

DISCUSSION

Among the components of external causes, LTA contribute significantly to high mortality in all societies, affecting all individuals without distinction.[3]

When investigating the mortality results according to age group (Table 2), individuals younger than 15 years and older than 55 years had much lower rates compared to the other groups with age groups between 20 and 54 years that had the highest rates. Similar differences when comparing age extremes have been reported by other authors.[8,12] Except for those aged 55-64 years, which showed a significant increase of 44.9% and those aged 75 and over with 5.9% from 2005 to 2015, there was a decrease or maintenance of mortality in all age groups.

The impact of more than one million Years of Potential Life Lost (YPLL) by LTA, especially within the young and productive age group (early mortality), in just one year in the country, represents an extreme social cost resulting from a death cause that could be prevented. Thus, greater advances in the prevention of mortality from LTA are necessary, considering the complexity of the factors involved and the unequal and iniquitous distribution of this problem in the Brazilian population.[1]

However, the accidents among males, which have not shown significant decreases in the rates, are of extreme relevance. The association among male gender, exposure to traffic accidents and mortality from this cause has been reported by several authors, as well as a tendency of temporal decrease among men and stabilization of rates among women.[8,13,14]

In our study we did not find an equivalent reduction in rates for both sexes (Table 2), with a drop of approximately 3% for males and an increase of 1% for females in the years 2010 and 2015. And when we evaluated the period from 2005 to 2015 we found a decrease of 2.3% for females and an increase of 0.6% for males.

According to Nardoto's study, men tend to be more violent due to cultural and biological injunctions, being thus more vulnerable to death by external causes, such as driving vehicles at higher speeds, riskier maneuvers, alcohol use, among others.[6,15] ATTs may be associated with several factors, such as deficient conservation of vehicles and roads, human error and consumption of psychoactive substances. Evidence shows a causal link between the consumption of alcoholic beverages and the occurrence of traffic accidents, considering the effects of this substance on the perception, vision, reflexes, consciousness and behavior of individuals who stop using seat belts and drive at high speed. In Brazil, until recently, the high rates of traffic accidents have always been associated with the lack of both legislation and adequate public policies in relation to this phenomenon.[16,17]

The reduction of the standardized mortality coefficient in the city of São Paulo found in our study (Table 3), in most of the regions studied, follows a worldwide trend. This decrease can be explained by the reduction in the average speed on urban roads resulting from the increase in the car and motorcycle fleet that occurred during the study period.

However the increase in the period from 2005 to 2015 was mainly due to the acquisition of cars and motorcycles, resulting from economic incentives such as tax exemption and increased availability of financing for the acquisition of these means of transportation.[18] Moreover, there was an increase in the purchasing power of middle- and lower-income populations, which encouraged the acquisition of individual private vehicles for their travel, due to the exemption of the Tax on Industrialized Products (IPI) for new vehicles.[7,19]

Preventive actions in traffic - such as the modification of the Lei Seca (Dry Law) in December 2012 (Law No. 12,760/2012), awareness campaigns, and stricter inspection of traffic infractions in the São Paulo capital - may also have influenced the stabilization of the coefficients analyzed.[14,20]

The law that deals with the prohibition of alcohol use in traffic has undergone intense reformulation, succeeding in decreasing the rate of alcohol use through breathalyzer tests, as well as greater rigor in the application of penalties.[21] Such measures were more intense between 2007 and 2013, especially during holidays and weekends, which may explain the decrease in these rates.[22]

The implementation of the new Brazilian Traffic Code, in effect since 1998, reduced traffic deaths in Brazil by up to 5.8%, representing

more than 26,300 lives saved, which is significant. In addition, there were savings of R$71 billion in lost production, health care, removal and transportation between 1998 and 2004.[4]

Studies showing the impact of specific public policies on the occurrence of traffic accidents are relevant, since they indicate both the public authorities and the general population the scope and effectiveness of the legal measures instituted.[2] The Ministry of Health develops several actions to address traffic violence. However, articulated and intersectoral actions involving the whole society are necessary, aiming to meet the goals of reducing morbidity and mortality from traffic accidents established in the Decade of Action for Road Safety from 2011 to 2020.[23]

An important limitation of this study concerns the use of secondary data. This hinders the control of possible confounding factors and the reliability of the information, which directly depends on the coverage and quality of death notification. Regarding the coverage of death records, although there are still gaps in data collection, these have decreased in Brazil, so that data have become increasingly reliable.[7]

We observed differences in magnitude and trend in the different regions of the municipality of São Paulo focused on the groups and regions at higher risk and with an increasing trend, as was the case in the western region, known for its large number of bars and frequented by many young people. The discrepancies between the results for the different regions of the city show that there is a need to carefully study the characteristics of each region so that health policies aimed at the prevention of LTA can be based on the reality of each region. Thus, LTAs continue to be a public health problem in the city of São Paulo, due to the high burden of morbidity and mortality, the economic costs, and the social impact, mainly due to the involvement of individuals in productive age.

Through the results of this research, it is evident that actions to promote and prevent traffic accidents should primarily focus on young males who live or visit peripheral neighborhoods (south, north and east). We can state that the results show that the laws referring to the Brazilian Traffic Code (CTB) and Prohibition Law have been determinant for the prevention of deaths by traffic accidents in the municipality of São Paulo.

CONCLUSION

The results obtained by comparing the years examined indicate there is a decrease in overall mortality of RTAs in most macro-regions. This resulted from preventive actions in traffic, such as the modification of the Prohibition Law, awareness campaigns and stricter inspection of traffic violations in the capital of the state of São Paulo. However, regarding actions to prevent traffic accidents, young males living in peripheral neighborhoods of the city (south, north and east) are the most susceptible group, and thus deserve further attention, according to the data analysis.

CONTRIBUTIONS OF THE AUTHORS: Each author contributed individually and significantly to the development of this article. FBT: study conception; RSS: writing of the study and final approval of the manuscript to be published; JJSHEB: data interpretation and writing of the study; JVS: data interpretation and writing of the study; MBSS: critical review of the intellectual content and writing of the study; PCS: study design and final approval of the manuscript to be published.

REFERENCES

1. Andrade SSCA, Mello-Jorge MHP. Mortalidade e anos potenciais de vida perdidos por acidentes de transporte no Brasil, 2013. Rev Saude Publica. 2016;50:59
2. Abreu DROM, Souza EM, Mathias TAF. Impacto do Código de Trânsito Brasileiro e da Lei Seca na mortalidade por acidentes de trânsito. Cad Saude Publica. 2018;34(8):e00122117.
3. Oliveira NLB, Souza EM, Cunha GZ. Mortality in traffic accidentes: temporary trend between 1996 and 2012. Cienc Cuid Saude. 2017;16(4):1-8.
4. Leitão PA, Bezerra IMP, Santos EFS, Ribeiro SL, Takasu JM, Carlesso JL, et al. Mortality due to traffic accidents, before and after the reduction of the average speed of motor vehicles in the city of São Paulo, Brazil, from 2010 to 2016. J Hum Growth Dev. 2019;29(1):83-92.
5. Moreira MR, Ribeiro JM, Motta CT, Motta JIJ. Mortalidade por acidentes de transporte de trânsito em adolescentes e jovens, Brasil, 1996-2015: cumpriremos o ODS 3.6? Cien Saude Colet. 2018;23(9):2785-96.
6. Cover DP, Nunes EAB, Carvalho KM. Mortalidade por acidentes de trânsito no Piauí: caracterização de casos no biênio 2012-2013. Rev Uninga. 2016 Jul-Sep;49:12-9.
7. Aquino EC, Neves M, Morais Neto OL. Tendências da mortalidade por acidentes de transporte terrestre no município de Goiânia, Brasil, 2006-2014..Epidemiol Serv Saude. 2018;27(4):e2017268.
8. Klabunde FC, Ghizzo Filho J, Freitas PF, Nazário NO. Impacto da Lei Seca na taxa de mortalidade por acidentes de trânsito, Santa Catarina, entre 2005 e 2011. Arq Catarin Med. 2017;46(2):108-17.
9. Ministério da Saúde (BR). Sistema de Informação de Mortalidade – SIM [Internet]. Brasília: Ministério da Saúde; 1975 - [accessed on 2019 Mar 11]. Available from: http://www2.datasus.gov.br/DATASUS/index.php?area=0901&item=1&acao=26&pad=31655
10. Juliano Y, Novo NF, Goihman S, Paiva ER, Leser W. Coeficiente padronizado de anos de vida perdidos, de Haenszel. Comparação com o coeficiente padronizado de mortalidade geral, quanto à utilização como indicador de nível de saúde de populações. Rev Saude Pública. 1987;21(2):108-22.
11. Cochran WG. Some methods for strengtering the comman X^2 test. Biometrics. 1954;10(4):417-51.
12. Oliveira ZC, Mota ELA, Costa MCN. Evolução dos acidentes de trânsito em um grande centro urbano, 1991-2000. Cad Saude Publica. 2008;4(2):364-72.
13. Mesquita Filho M, Silva FM, Veiga VT. Acidentes de trânsito ocorridos antes e depois da legislação restritiva ao consumo de bebidas alcoólicas. Rev Med Minas Gerais. 2012;22(3):259-64.
14. Bacchieri G, Barros AJD. Acidentes de trânsito no Brasil de 1998 a 2010: muitas mudanças e poucos resultados. Rev Saude Publica. 2011;45(5):949-63.
15. Nardo EML, Diniz JMT, Cunha CEG. Perfil da vítima atendida pelo serviço pré-hospitalar aéreo de Pernambuco. Rev Esc Enferm. 2011;45(1):237-42.
16. Nunes MN, Nascimento LFC. Análise espacial de óbitos por acidentes de trânsito, antes e após a Lei Seca, nas microrregiões do estado de São Paulo. Rev Assoc Med Bras. 2012;58(6):685-90.
17. Cunha FV, Julien TMS, Santos JCS. Characterization of car accidents in the city of Guaratinguetá, Brazil involving motorcycles. Rev Enferm UFPE. 2011;5(5):1112-20.
18. Morais Neto OL, Beniz LAF, Rodrigues FR, Botacin CF, Mandacarú PMP, Oliveira IV, et al. Tendências de mortalidade por acidentes de trânsito pós redução de IPI. Rev Goiana Med. 2016;49(1):6-10.
19. Instituto de Pesquisa Econômica Aplicada (BR). Nota técnica: impactos da redução do imposto sobre produtos industrializados (IPI) de automóveis [Internet]. Brasília: Instituto de Pesquisa Econômica Aplicada; 2009 [accessed on 2018 Jul 10]. Available from: http://ipea.gov.br/agencia/ images/stories/PDFs/2009_nt015_agosto_dimac.pdf
20. Brasil. Lei nº 12.760, de 20 de dezembro de 2012. Altera a Lei nº9.503, de 23 de setembro de 1997, que institui o Código de Trânsito Brasileiro. Diário Oficial da União. 2012 Dez 21;1:1.
21. Alves ACBB, Oliveira AS, Pedro JB, Mamlak L, Oliveira LS, Mendonça LO, et al. A nova lei seca: mudanças ocasionadas pela antiga e nova lei no código de trânsito brasileiro. Cad Grad Cienc Hum Sociais. 2014;2(2):137-46.
22. Malta DC, Berna RTI, Silva MMA, Claro RM, Silva JB Jr., Reis AAC. Consumo de bebidas alcoólicas e direção de veículos, balanço da lei seca, Brasil 2007 a 2013. Rev Saude Publica. 2014;48(4):692-6.
23. World Health Organization, United Nations Road Safety Collaboration. Global Plan for the Decade of Action for Road Safety, 2011-2020 [Internet]. Geneva: World Health Organization; 2010 [accessed on 2020 Apr 15]. Available from: https://www.who.int/roadsafety/decade_of_action/plan/en/

DOI: http://dx.doi.org/10.1590/1413-785220212904243419

BROAD PECTUS EXCAVATUM TREATMENT: LONG TERM RESULTS OF A BRAZILIAN TECHNIQUE

TRATAMENTO DO PECTUS EXCAVATUM AMPLO: RESULTADOS A LONGO PRAZO DE UMA TÉCNICA BRASILEIRA

Davi de Podestá Haje[1,2], Sydney Abrão Haje (in memoriam) [1], José Batista Volpon[3], Ana Carolina Oliveira da Silva[2], Leonardo Ferreira Braz Lima[2], Wilson Huang[2]

1. Centro Clínico Orthopectus, Brasília, DF, Brazil.
2. Hospital de Base do Distrito Federal, Department of Orthopedic Surgery, Brasília, DF, Brazil
3. University of São Paulo, School of Medicine of Ribeirão Preto, Department of Biomechanics, Medicine and Rehabilitation of the Locomotor System, Ribeirão Preto, SP, Brazil.

ABSTRACT

Objective: This study aims the treatment results of broad pectus excavatum after a long-term follow-up and skeletal maturity. Methods: Eighty-four children and adolescents with broad-type pectus excavatum were selected for evaluation after treatment with a dynamic orthosis that applies compression to the lower rib projections and prescription of exercises. The broad pectus excavatum was defined as a deformity that the depressed area was greater and covered the area above and below the nipple line. All patients were evaluated for more than 1 year after the end of treatment and skeletal maturity. Post-treatment results were categorized as mild, moderate and severe. Statistic correlations between results and deformity flexibility, deformity severity, and adherence to treatment were assessed. Results: The mean age at the beginning of treatment was 13.3 years, and the follow-up duration was 25.7 months after suspension of orthosis use. Forty-eight percent of patients showed good results. With regular use of orthoses and performance of exercises, this rate increased to 70% ($p < 0,001$). Mild cases showed more success than severe cases ($p = 0,007$). Initial flexibility didn't influence the results ($p = 0,63$). Conclusion: Treatment of broad pectus excavatum with orthoses and exercises led to good definitive results in most resilient patients, especially in those with mild deformities. ***Level of Evidence V, Expert Opinion***.

Keywords: Braces. Funnel Chest. Pectus Excavatum. Orthotic Devices. Thoracic Wall.

RESUMO

Objetivo: Estudar os resultados de longo prazo e com seguimento até a maturidade esquelética do tratamento do pectus excavatum amplo. Métodos: 84 crianças e adolescentes foram tratados com uma órtese que aplicacompressão nas saliências costais inferiores, associada a exercícios específicos. A deformidade foi classificada como ampla quando a depressão tem maior extensão e abrange uma área acima e abaixo da linha mamilar. Os resultados foram categorizados em ruim, regular ou bom, sendo correlacionados estatisticamente com a flexibilidade, a gravidade da deformidade e a adesão ao tratamento, com avaliação um ano após o fim do tratamento e na maturidade esquelética. Resultados: A idade média no início do tratamento foi de 13,7 anos e o seguimento médio foi de 25.7 meses após a suspensão do uso da órtese. 48% dos casos apresentaram sucesso com o tratamento, mas quando os exercícios e o uso da órtese foram regulares, esta taxa aumentou para 70% ($p < 0,001$). Os casos mais leves tiveram maior sucesso que os de maior gravidade ($p = 0,007$), mas a flexibilidade inicial não influenciou os resultados ($p = 0,63$). Conclusão: O tratamento do pectus excavatum amplo com o uso de órtese e exercícios apresentou bons resultados definitivos na maioria dos pacientes resilientes, em especial nos casos mais leves. ***Nível de Evidência V, Opinião do Especialista.***

Descritores: *Braquetes. Tórax em Funil. Pectus Excavatum. Aparelhos Ortopédicos. Parede Torácica.*

Citation: Haje DP, Haje AS, Volpon JB, Silva ACO, Lima LFB, Huang W. Broad *pectus excavatum* treatment: long term results of a brazilian technique. Acta Ortop Bras. [online]. 2021;29(4):197-202. Available from URL: http://www.scielo.br/aob.

INTRODUCTION

In pectus excavatum, we can observe an area of depression that can be localized or broad, symmetrical or asymmetrical and may be associated with varying degrees of lower costal arch protrusions.[1-3] The most common reasons that patient or family members opt for treatment of these deformities are embarrassment and body-image issues.[4] Severe pectus excavatum deformities may be associated with exercise intolerance and shortness of breath.[5]

The most widely used treatment for pectus excavatum is surgery.[6] Another option is non-invasive treatment with use of a brace and performance of specific physical exercises. This technique was initially described by Haje in 1979,[7] followed by reports of good results in a large percentage of patients with pectus carinatum.[8,9]

All authors declare no potential conflict of interest related to this article.

The study was conducted at Centro Clínico Orthopectus, DF, Brazil
Correspondence: Davi P. Haje. SMHN 2 Bloco A, Ed. Clínicas, sala 804-806, Brasília, DF, Brazil. 70710904. davihaje@yahoo.com.br

Article received on 09/10/2020, approved on 11/05/2020.

Intuitively, constant pressure on the anomalous protrusion can lead to bone remodeling and permanent correction of the deformity. Although much less is known about brace use for the treatment of pectus excavatum. In this case, the orthosis has a compressive effect on the protrusion of the last ribs by lowering them, indirectly causing bone depression elevation with the performance of specific exercises. This technique was developed by Haje et al.[1-3,9,10] who reported that the application of a standardized treatment protocol is an important factor for achieving good results, especially in more flexible cases.[1,9,10] But previous Haje's studies did not describe the brace and exercise treatment long term results for pectus. It is important to follow patients with musculoskeletal deformities (like clubfoot, pectus and others) treated in conservative or surgically ways until their growth period ends because it is possible to have relapses and the final result may change.[6,11]

In addition to this orthosis, reports describes non-surgical treatment of pectus excavatum using a device called the Vacuum Bell®;[12] use of the dynamic chest compressor (DCCII) is associated with Vacuum Bell.[1,13]

This study targets the assess long-term results of a non-invasive method for correction of broad-type pectus excavatum using the method described by Haje,[9] involving a special orthosis for use with specific physical exercises.

MATERIALS AND METHODS

Patients were treated between 1977 and 2017 according to a pre-established protocol and supervised by one of the authors (DPH or SAH). Overall, 573 patients with broad-type pectus excavatum were identified. We excluded 141 untreated patients (105 with non-indications for treatment and 36 patients who did not consent to therapy), those with follow-up of less than one year (n=125), those with an iatrogenic etiology (n=2), those who had used a vacuum bell (n=14), and those who ceased treatment (n=31). Patients who did not attend a follow-up after 1 year of treatment completion and at skeletal maturity were also excluded (n=176) because the study objective was not to verify the immediate or short term results. Only patients who were followed-up for more than 36 months and 12 months after they had finished growing were included, totalizing 84 patients.

Pectus excavatum was classified as broad when the deformity was greater and covered an area above and below the nipple line (Figure 1).[1,2,3] The other form of pectus excavatum is localized and will be evaluated in another publication.

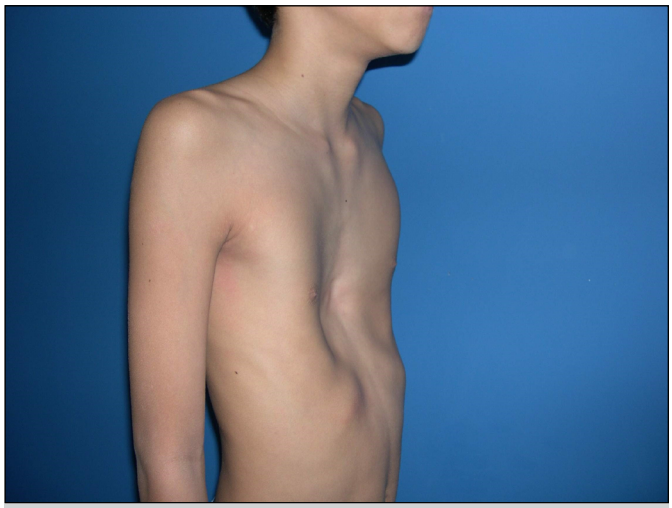

Figure 1. Broad-type pectus excavatum. The area of deformity is extensive and often presents with changes to the lower coastal arch cage which compromises aesthetics.

The deformities were classified as mild, moderate, or severe based on clinical findings and as determined by the physician (Figure 2). The flexibility of the deformity was evaluated using a manual compression maneuver of the lower rib cage in the anteroposterior direction performed by the examiner. Simultaneously, patients were asked to perform the Valsalva maneuver together with adduction against upper limb resistance. Younger patients were requested to blow a balloon. The effect of this maneuver on the excavatum was observed. The deformity was classified as "flexible" when there was complete reversal of the depression, "rigid or poorly flexible" when the depression did not change or changed slightly, and "moderately flexible" with partial correction (Figure 3).[9] Physical examination was performed only by the first or second author.

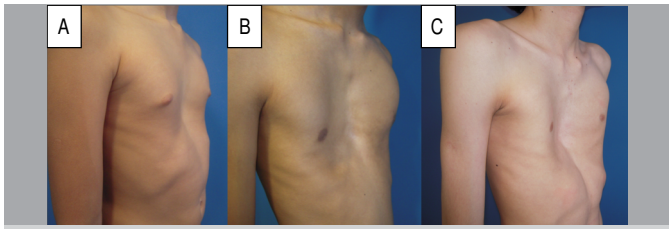

Figure 2. Classification of the severity of broad-type pectus excavatum, according to aesthetic impairment. (A) Mild; (B) Moderate; (C) Severe.

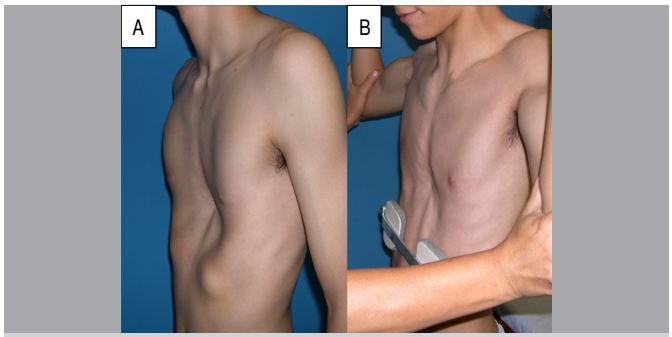

Figure 3. (A) Flexibility test for pectus excavatum; (B) with compression of the lower rib cage, in this case performed by the dynamic chest compressor itself.

Treatment was indicated for moderate or severe deformities in children and adolescents. Treatment was indicated in some mild cases when the pectus was noteworthy to the adolescent and accepted by the family. We indicated treatment before puberty especially if the deformity started getting worse. Adolescents with hyperkyphosis were encouraged to start treatment. Patients with mild scoliosis (less than 20° curvature as determined using the Cobb radiographic method) associated with the pectus (regardless of its severity) were also encouraged to start treatment. Only growing individuals with personal and family motivation and acceptance were treated.

The orthosis is shown in Figure 4. Patients were instructed to wear the orthosis 23 hours per day (minimum 18 hours). Removal was allowed during the day for aquatic activities and contact sports. The compression force was controlled by the patient and maintained at a comfortable level. Progressive compressive adjustment was interrupted when the costal salience disappeared. Along with the use of the orthosis, specific exercises were recommended to strengthen the muscles of the anterior chest wall. Weaning from the orthosis was performed gradually until the minimum usage period of 24 months was completed.



Figure 4. Type of brace used for the treatment of broad-type pectus excavatum. The two anterior cushions exert pressure on the last costal arches and are connected to a posterior cushion by means of a threaded bar that serves to control the compression force.

Adherence to treatment was classified as irregular when the orthosis was not used for the prescribed time, or no regular performance of the physical exercises. Patients who ceased orthosis use before discharge were excluded; but those who only ceased performing the exercises before the recommended period were classified as showing irregular adherence. Results were considered poor when the deformity did not change or worsened, average when there was under-correction, and good when there was significant improvement. The treatment results were analysed by either the first or second author of this manuscript. Treatment satisfaction was reported by the family (when the patient was a child) or by the adolescent patient as "satisfied" or "not satisfied". Treatment success was defined as a good result and if the patient was satisfied. All patients were photographed in the same positions, before and after treatment, and clinical images were used in the evaluation. The comparative group consisted of individuals who met indication for treatment but refused and then returned for re-evaluation.
The evaluation protocol was approved by our Institutional Ethics Committee (58417516.3.0000.5553).

Statistical analysis

The chi-square test (χ^2) was used in the analysis of categorical variables and also Cochran-Mantel-Haenszeltest to determine whether the odds ratios between two variables remained the same for categories of a third variable. The level of significance was $p \leq 0.05$. The Statistical Package for Social Sciences (SPSS) v.22.0 (IBM Corp., Armonk, NY, USA) was used for all statistical analyses.

RESULTS

The mean age at the beginning of treatment was 13.3 years (standard deviation [SD] = 3.5 years; median = 13,0 years, variation 4,8-17,8), being 19% (n = 16) less than 10 years old. The age histogram of the 84 treated patients that completed the follow-up is shown in Figure 5. Of the treated patients, 66 (79%) were male and 18 (21%) were female. The mean follow-up duration was 25.7 months after the end of treatment.

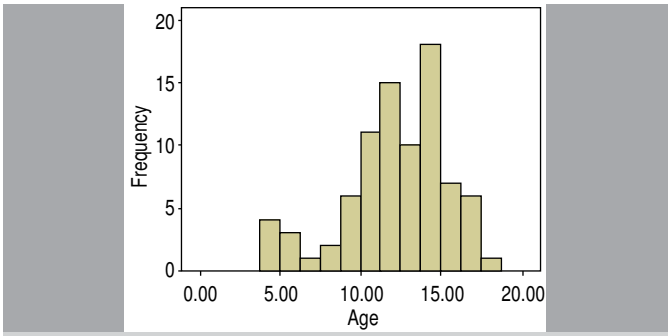

Figure 5. The histogram of age of the treated patients that completed the follow-up.

Eleven patients (13%) presented with mild initial deformity, 55 (66%) were moderate, and 18 (21%) were severe. The deformities were very flexible or moderately flexible in 50 patients (59 %) and were rigid or not very flexible in 34 patients (41%).
Results were considered good in 40 patients (48%), average in 36 patients (43%), and poor in eight patients (9%). Figures 6 and 7 show a good result. Treatment satisfaction was reported in all patients with good results, in 20% (n = 17) of those with average results and in none with poor results.

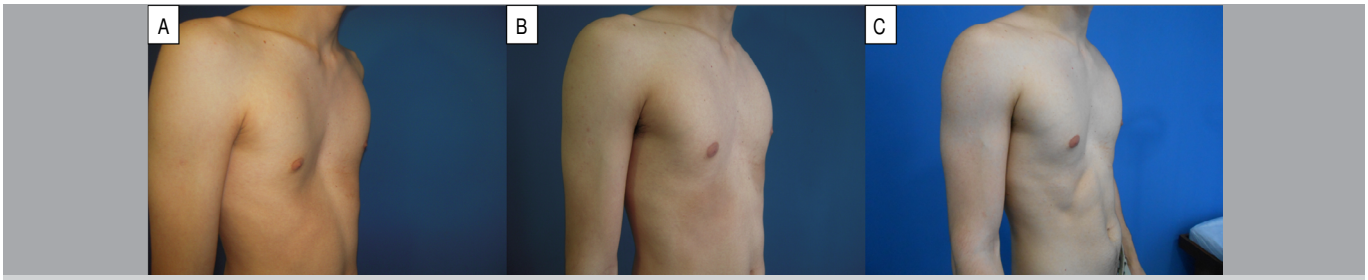

Figure 6. A patient aged 15 years and 6 months at the beginning of treatment (A), with good results obtained less than 12 months after the beginning of treatment and maintained improvements after 28 months of follow-up (B), with maintenance of correction at 23 years-of-age, with 9 years of follow-up, and 5 years after complete interruption of treatment (C).

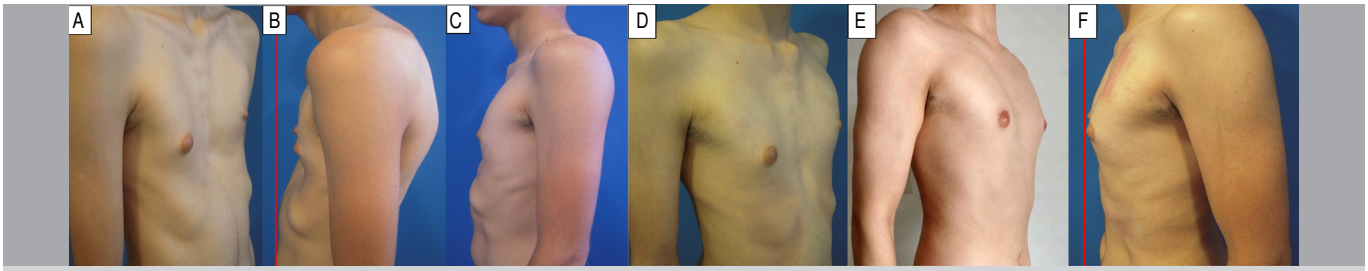

Figure 7. (A) A patient aged 13 years and 6 months showing pectus excavatum and hyperkyphosis (B_ with natural posture; (C) and with posture corrected by the examiner, (D) with a good result after 3 months of treatment, which was maintained regularly until 15 years and 6 months of age, when orthoses weaning started, (E) with results maintained after 6 years of follow-up, and after 3 years of treatment interruption. He presented with correction of hyperkyphosis and protrusion of the lower ribs (see improvement of the positioning of the red line before treatment in B and C, and at treatment end in F).

Good results were achieved in 72% (n = 8) with mild deformities, 47% (n = 26) with moderate deformities, and 33% (n = 6) with severe deformities. Mild cases showed more success than severe cases (p = 0,007).
Regarding flexibility, the results were good in 48% (n = 24) with flexible or moderately flexible deformities and 47% (n = 16) with rigid or less flexible deformities.
The use of brace was regular in 69% (n = 58) and irregular in 31% (n = 26). Overall, 54% (n = 45) of patients performed the specific exercises regularly, while 46% (n = 39) performed these irregularly. When flexibility was analyzed in isolation, no significant differences is shown among the various results (p = 0,63). Even when flexibility was analyzed together with the regularity of the use of the orthosis and performance of the exercises, there was no significant influence on the response to treatment (p = 0,67).
Seventy percent of patients with regular orthosis use and exercise performance achieved good results (p < 0,001). By contrast, when orthosis use was irregular, regardless of the regular performance of the exercises, only 29% of patients achieved good results (p = 0,84). Table 1 shows the associations between variables.

Table 1. Comparisons made and interpretation of results

Comparison	χ^2 value / P / odds ratio and C.I.95%	Association between variables
Good results vs. pectus severity	16,3 / p = 0,007 / 3,8 (1,1-13,4)	Negative
Good results vs. pectus flexibility	0,23 / p = 0,63 / 0,84 (0,42-1,7)	No correlation
Good results vs. regular orthotic wearing	24,68 / p < 0,001/ 10,65 (1,74-17,9)	Positive
Good results vs. regular physical exercises	8,57 / p = 0,04 / 4,36 (2,4-8,89)	Positive
Good results vs. regular orthotic wearing and regular physical exercises	15,68 / p < 0,001 / 5,22 (2,15-12,64)	Positive
Good results vs. irregular brace wearing and regular physical exercises	3,35 / p = 0,84 / 1,22 (0,38-3,27)	No correlation

No major complications were observed; but skin irritation or transient hyperpigmentation occurred in the areas of pressure in about 4% of patients. In 12% of patients, was identified discomfort or transient pain in the orthosis support areas, both of which resolved with partial release of pressure. These complications did not lead to an interruption in orthosis use. Relapses in those patients that completed the follow-up were not showed.
Thirty-six patients or family members did not accept treatment; however, nine returned to be re-evaluated. Seven of these (78%) presented worsening of the deformity (Figure 8) and two were stable. All patients with worsening of deformity presented with moderate or marked deformities, with four (57%) defined as moderately flexible and three (43%) defined as rigid at the last evaluation (approximately 15.2 years of age). Some treated patients who presented with some improvement returned with recurrence of the deformity when they stopped the treatment before medical orientation (n = 5) (Figure 9).

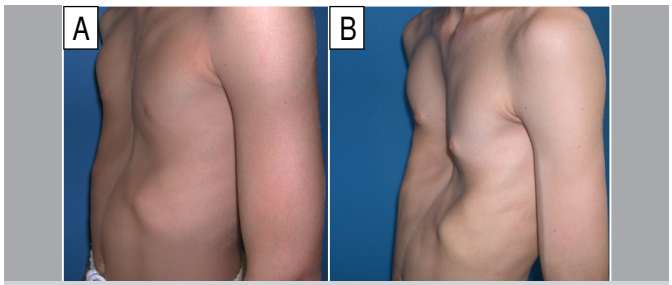

Figure 8. (A) A 10-year-old boy with moderate deformity, where the family did not accept the indication for treatment. (B) At 14 years-of-age, the deformity is worse (B).

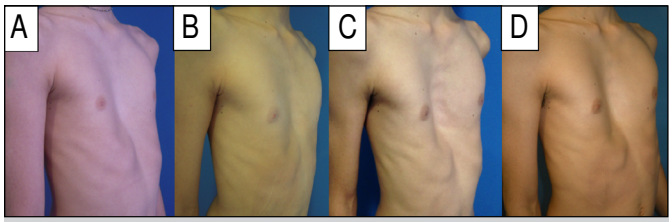

Figure 9. (A)The patient started treatment at 12 years of age; (B) with good results after 12 months of regular orthosis use and irregular exercise adherence. (C) Besides, the patient abandoned treatment. In adolescence, the deformity recurred, and treatment was restarted. (D) After 1 year, there was some improvement.

In two patients, a slight hypercorrection (depressed area turned into a pectus carinatum) was presented and managed by reducing the orthosis DCC II usage time or the use of a second orthosis for the treatment of pectus carinatum, called DCC I (Figure 10).

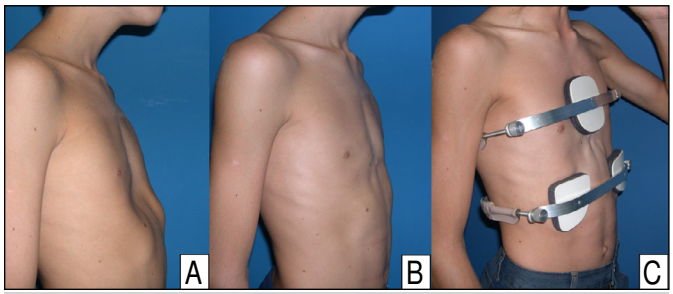

Figure 10. (A) An 11-year-old boy with moderate excavatum deformity who presented with hypercorrection; (B) after 24 months of treatment with development of mild pectus carinatum; (C) that was controlled using another orthosis.

DISCUSSION

In terms of treatment, surgical correction of pectus is considered by most surgeons as the only effective option. The aesthetic results of surgery are not always the desired ones; for example, the possibility of maintaining prominent costal edges and the possible appearance of a reactive pectus carinatum is accepted.[14] Still, surgery poses serious complications, and life-threatening complications are often underestimated, including subsequent removal of the implant.[15] This makes the decision to proceed with surgical treatment very difficult for some patients, especially those with mild or moderate pectus.
When choosing initial pectus treatment for growing patients, we recommend first considering non-invasive treatment methods such as those based on orthosis use (bracing) and physical exercises,as a low-risk method with the possibility of interruption in cases of

intolerance or change of opinion is possible. Failure to recommend treatment in cases of skeletally immature pectus excavatum may constitute negligence because the patient's condition may worsen during their growth and because milder deformities showed better. In our opinion, surgery should be indicated for patients who cannot adapt or did not show good results with the available conservative therapy, as well as those who have severe deformities and psychological issues. Finally, the patient and their family must accept the risks imposed by surgical treatment.

48% of the patients, had good results, suggesting that the broad form of pectus excavatum can be efficiently corrected using the non-invasive method described here as a group of patients followed skeletal maturity. Haje and Haje (2009),[3] who treated localized and broad pectus excavatum with a brace and exercises, reported good results in 29% and 21% of patients after a follow-up of less than 1 year, respectively. Moon et al.[16] reported that their results were long-term; despite, they accepted a minimum follow-up of only 13 months in cases of pectus carinatum treated with orthosis; we believe that a longer observation period to growth stabilization and an additional observation period after finishing treatment are essential.

In pectus excavatum, the pressure exerted by the orthosis on the lower anterior costal arches associated with exercises probably increased the pressure in the mediastinum with consequent expansion of the osteo-cartilaginous structures of the chest's anterior face, modifying the forces that act on the various growth plates and contributing to the remodeling of deformed structures. Wolff's law[17] explains the remodeling process of skeletal structures. Wong and Carter reported that mechanical forces on the sternum may influence skeletal morphogenesis.[18] In PE (pectus excavatum) patients, who reportedly have increased midline excursion at the umbilicus level,[19] the braces and specific exercises might help limit that excursion. The action of the diaphragm may become more efficient to expand the chest as the protrusions of the costal edges are corrected by presence of the orthosis. The performance of specific and repetitive exercises associated with orthosis use, along with holding the maximum inspiration during muscle contraction, works actively to correct the depressed area of the pectus and stimulates postural improvement.

This study highlights some prognostic factors that are very useful during the initial treatment period. A positive correlation between good results and treatment adherence is observed, including regular orthosis use and regular performance of the associated exercises. We believe that pectus excavatum treatment with the use of orthoses and exercises should begin fast because we found that more severe deformities were related to worse results. Despite that, the correlation between flexibility and good results is not showed. Haje et al.[1,3] found that flexibility was an important prognostic factor in the treatment with orthoses and specific exercises.

The method used in this study had a low rate of complications. The most frequent complication was skin irritation, which did not lead to treatment interruption.[1,3] The other rare complication, hypercorrection,[10] was very well managed with treatment adjustment and use of an orthosis used for reactive pectus carinatum.

Some limitations were shown in this study, most of which were based on subjective criteria used to define pectus type, its severity and flexibility. This limitation could be minimized with image evaluation methods that do not involve exposure to radiation, such as 3D structured light scanners,[20] but this exam was not currently available The authors were concerned about using a CT before and after treatment because of radiation, costs and that would not change the braces and treatment indication criteria. Besides, the description of an objective flexibility test for pectus excavatum was not identified. The authors think that analyze results using photos in the same position before and after treatment is enough. The fact that all patients classified as a good result by the authors had satisfaction with their final result, brings more credibility to the treatment results.

CONCLUSION

In conclusion, we found that the non-invasive method for broad-type pectus excavatum correction presents good results in the patients followed until skeletal maturity and those who adhered to the treatment protocol, although it is a long treatment process that may lead to short or late loss of follow-up, treatment irregularity, or abandonment of treatment before the deformity is stabilized.

AUTHORS' CONTRIBUTIONS: Each author contributed individually and significantly to the development of this article. DPH: conceived and planned the activities that led to the study, participated in the review process, performed the treatment together with Sydney Haje from 1999 to July 22th 2011, and by himself since this last date, interpreted the results of the study and approved the final version; SAH (*in memoriam)*: Performed the treatment from 1988 to July 22th 2011 (3 days before he passed away); JBV manuscript preparation, participated in the review process and approved the final version; ACOS: data collection and approved the final version; LFBL: data collection and approved the final version; WH: data collection and approved the final version.

REFERENCES

1. **Haje SA, Haje DP, Silva M. Chest and shoulder girdle. In: Herbert S, Barros Filho TEP, Xavier R, Pardini Júnior AG, editors. Orthopedics and traumatology: principles and practices. 5th ed. Porto Alegre: Artmed; 2017. p. 81-100.**
2. Haje SA. Pectus deformities: new concepts and orthopedic approach in children and adolescents – 1st part. Rev Bras Ortop. 1995;30(1/2):75-9.
3. Haje SA, Haje DP. An orthopaedic approach of the pectus deformity: 32 years of studies. Rev Bras Ortop. 2009;44(3):193-200.
4. Steinmann C, Krille S, Mueller A, Weber P, Reingruber B, Martin A. Pectus excavatum and pectus carinatum patients suffer from lower quality of life and impaired body image: a control group comparison of psychological characteristics prior to surgical correction. Eur J Cardiothorac Surg. 2011;40(5):1138-45.
5. Chao CJ, Jaroszewski DE, Kumar PN, Ewais MM, Appleton CP, Mookadam F, et al. Surgical repair of pectus excavatum relieves right heart chamber compression and improves cardiac output in adult patients--an intraoperative transesophageal echocardiographic study. Am J Surg. 2015;210(6):1118-25.
6. Nuss D, Obermeyer RJ, Kelly RE Jr. Pectus excavatum from a pediatric surgeon's perspective. Ann Cardiothorac Surg. 2016;5(5):493-500.
7. Haje SA, Raymundo JLP. Considerations on the deformities of the anterior thoracic wall and presentation of a non-invasive treatment for the protusion forms. Rev Bras Ortop. 1979;14(4):167-78.
8. Cohee AS, Lin JR, Frantz FW, Kelly RE Jr. Staged management of pectus carinatum. J Pediatr Surg. 2013;48(2):315-20.
9. Haje SA, Bowen JR. Preliminary results of orthotic treatment of pectus deformities in children and adolescents. J Pediatric Orthop. 1992;12(6):795-800.
10. Haje SA, Haje DP. Overcorrection during treatment of pectus deformities with DCC orthoses: experience in 17 cases. Int Orthop. 2006;30(4):262-7.
11. Luckett MR, Hosseinzadeh P, Ashley PA, Muchow RD, Talwalkar VR, Iwinski HJ, et al. Factors predictive of second recurrence in clubfeet treated by ponseti casting. J Pediatr Orthop. 2015;35(3):303-6.
12. Haecker FM. The vacuum bell for conservative treatment of pectus excavatum: the Basle experience. Pediatr Surg Int. 2011;27(6):623-7.
13. Haje DP. Association of braces and exercises to vacuum bell for the treatment of pectus excavatum. J Pediatr Surg Spec. 2015;9:23.
14. Swanson JW, Colombani PM. Reactive pectus carinatum in patients treated for pectus excavatum. J Pediatr Surg. 2008;43(8):1468-73.

15. **Hebra A. Minor and major complications related to minimally invasive repair of pectus excavatum. Eur J Pediatr Surg. 2018;28(4):320-6.**
16. **Moon DH, Kang MK, Lee HS, Lee S. Long-term results of compressive brace therapy for pectus carinatum. Thorac Cardiovasc Surg. 2019;67(1):67-72.**
17. Wolff J. The law of bone remodeling. Berlin: Springer; 1986.
18. Wong M, Carter DR. Mechanical stress and morphogenetic endochondral ossification of the sternum. J Bone Joint Surg Am. 1988;70(7):992-1000.
19. Redlinger RE Jr, Kelly RE, Nuss D, Goretsky M, Kuhn MA, Sullivan K, et al. Regional chest wall motion dysfunction in patients with pectus excavatum demonstrated via optoelectronic plethysmography. J Pediatr Surg. 2011;46(6):1172-6.
20. **Uccheddu F, Ghionzoli M, Volpe Y, Servi M, Furferi R, Governi L, et al. A novel objective approach to the external measurement of pectus excavatum severity by means of an optical device. Ann Thorac Surg. 2018;106(1):221-7.**

DOI: http://dx.doi.org/10.1590/1413-785220212904241648

DIRECT PEDICLE SCREW INSERTION PULLOUT STRENGTH

RESISTÊNCIA AO ARRANCAMENTO DO PARAFUSO PEDICULAR DE INSERÇÃO DIRETA

Rômulo Pedroza Pinheiro[1], Ariane Zamarioli[1], Thibault Chandanson[2], Keri George[3], Antonio Carlos Shimano[1], Helton Luiz Aparecido Defino[1]

1. Universidade de São Paulo, Faculdade de Medicina de Ribeirão Preto, Departamento de Ortopedia e Anestesiologia, Ribeirão Preto, SP, Brazil.
2. Université de Technologie de Belfort, Paris, France.
3. University of Calgary, Alberta, Canada.

ABSTRACT

Objective: Study the *in vitro* pullout strength of SpineGuard/Zavation Dynamic Surgical Guidance Z-Direct Screw (DSG Screw), a screw pedicle designed to be inserted using a direct insertion technique. Methods: DSG Screws of 5.5 mm and 6.5 mm were introduced into polyurethane blocks with a density of 10 PCF (0,16 g/cm^3). According to the experimental group, screws were inserted without pilot hole, with pilot without tapping, undertapping and line-to-line tapping. Screw pullout tests were performed using a universal test machine after screw insertion into polyurethane blocks. Results: Screws inserted directly into the polyurethane blocks without pilot hole and tapping showed a statistically higher pullout strength. Insertion of the screw without tapping or with undertapping increases the pullout screw strength compared to line-to-line tapping. Conclusion: DSG Screw showed the highest pullout strength after its insertion without pilot hole and tapping. ***Level of Evidence V, Expert Opinion.***

Keywords: Pedicle Screws. Spinal Fusion. In Vitro Techniques. Tensile Strength.

RESUMO

Objetivo: Estudar a resistência ao arrancamento in vitro do parafuso de inserção direta da SpineGuard/Zavation (parafuso DSG), um parafuso pedicular projetado para ser inserido usando a técnica de inserção direta. Métodos: Parafusos DSG de 5,5 mm e 6,5 mm foram introduzidos em blocos de poliuretano com densidade de 10 PCF (0,16 g/cm3). De acordo com o grupo experimental, os parafusos foram inseridos sem orifício piloto, com orifício e sem macheamento e macheamento diâmetro inferior com mesma geometria. Os testes de resistência dos parafusos foram realizados usando uma máquina de teste universal após a inserção dos parafusos nos blocos de poliuretano. Resultados: Os parafusos inseridos diretamente nos blocos de poliuretano sem orifício piloto e sem macheamento apresentaram uma resistência de arrancamento com significância estatística maior. A inserção do parafuso sem macheamento ou com macheamento com diâmetro inferior apresenta maior resistência ao arrancamento em comparação com o macheamento do mesmo diâmetro. Conclusão: O parafuso DSG apresentou a maior resistência ao arrancamento após sua inserção sem orifício piloto e sem macheamento. ***Nível de Evidência V, Opinião do Especialista.***

Descritores: *Parafusos Pediculares. Fusão Vertebral. Técnicas In Vitro. Resistência à Tração.*

Citation: Pinheiro RP, Zamarioli A, Chandanson T, George K, Shimano AC, Defino HLA. Direct pedicle screw insertion pullout strength. Acta Ortop Bras. [online]. 2021;29(4):203-206. Available from URL: http://www.scielo.br/aob.

INTRODUCTION

The pedicle of lumbar and thoracic spine has been extensively used as implant anchorage in the spinal surgery. The biomechanical advantages of pedicle screw-based system and the clinical usefulness is supported by the reports of high rate of fusion, deformity correction and clinical outcomes.[1]

The use of pedicle screw is related to two topics that still are a challenge in the field of spinal surgery: accuracy of pedicle screw and exposure of surgeon to radiation.[2]

To improve accuracy and reduce radiation exposure, a Dynamic Surgical Guidance – DSG, called PediGuard® probe was developed. This probe has the ability to identify different tissues by measuring electrical conductivity.[2-4] This device produces a sound, in which changes in pitch and cadence indicates a change in tissues around the tip of PediGuard® probe. A mid-range pitch and cadence audio signal is produced as the probe is in the cancellous bone. A low cadence pitch and cadence audio signal is performed as the probe approaches the pedicle cortical wall and it is the first indication of a potential pedicle breach.[3-5] The ability of Dynamic Surgical Guidance-DSG (PediGuard ®probe) to improve pedicle screw accuracy and to reduce radiation exposure has been shown in vitro using human cadaver specimens as well as in clinical trials.[6]

All authors declare no potential conflict of interest related to this article.

The study was conducted at Laboratório de Bioengenharia da Faculdade de Medicina de Ribeirão Preto da Universidade de São Paulo.
Correspondence: Rômulo Pedroza Pinheiro. Av. Bandeirantes 3900, Ribeirão Preto, SP, Brazil, 14049900. romulopinheiro@usp.br

Article received on 07/30/2020, approved on 09/24/2020.

A further development of Dynamic Surgical Guidance technique was the combination of Dynamical Surgical Guidance technology and a pedicle screw in just one device to develop a "A Dynamic Surgical Guidance Screw" (DSG Screw). The DSG Screw is a pedicle screw system with a breach anticipation sensor located at the tip of the screw. The device provides a real-time surgical guidance and the ability to insert directly the screw into the pedicle without drilling a pilot hole neither tapping.[7] The screw can be introduced directly into the pedicle and redirected during insertion according to the pitch and cadence of the audio signal. Besides, the DSG Screw insertion into the pedicle without drilling it do not require fluoroscopy for guidance, reducing intra-operative radiation and the operating time.

This study experimentally evaluate the pullout strength of DSG screw using the direct screw insertion technique. We tested the hypothesis that smart screw has higher pullout strength after its insertion directly in the block without pilot hole and tapping.

MATERIALS AND METHODS

One hundred and five polyurethane blocks of 8 cm height, 5 cm width and 5 cm length, with a density of 10 PCF (0.16 g/cm^3) (National Ltda.) were used as test bodies to introduce screws and to perform the mechanical pullout tests. SpineGuard/Zavation Dynamic Surgical Guidance Z-Direct Screw (DSG Screw of 5.5 mm and 6.5 mm outer diameter and 40 mm length) were inserted into the blocks according to the experimental group (Figure 1). The experimental groups were formed according to the use of pilot hole and tap diameter (undertapping and line to line). Thread taps 4.5 mm, 5.5 mm and 6.5 mm were used. The 4.5 mm tap was used as undertap for 5.5 mm screws. The 5.5 mm tap was used as undertap for 6.5 mm. All taps have a 2.9 mm pitch and a double lead design.

The screws were inserted into the blocks according to the experimental group. Each experimental group was formed by ten polyurethane blocks. For the 5.5 mm screws there were four experimental groups, and the screws were inserted: 1 – directly into the polyurethane block (without previous pilot hole and tapping), 2 – with a 2mm pilot hole without tapping, 3 – undertapping (2 mm pilot hole and 4.5mm tap), 4 – line to line (2 mm pilot hole and 5.5 tap). For the 6.5 mm screws there were five experimental groups: 1 – directly into the polyurethane block (without previous pilot hole and tapping), 2 – with a 2 mm pilot hole without tapping, 3 – undertapping (2 mm pilot hole and 4.5 mm tap), 4 – undertapping (2 mm pilot hole and 5.5 mm tap), 5 – line to line (2 mm pilot hole and 6.5 tap).

After screw insertion, pullout strength was evaluated using universal test machine (EMIC-DL10000, São José dos Pinhais, PR, Brazil). A rod was attached to the head of the screw and pullout force was applied vertically. This force was applied at a speed of 2.0 mm/min until the screw was pulled out of the polyurethane block.

Statistical methods

Continuous variables were expressed as the means and standard deviations (SD). The results from pullout forces were subjected to statistical analysis of normality using the Kolmogorov–Smirnov test, in order to determine the behavior of the data. The results obtained in the four groups were compared using three-way analysis of variance, followed by Tukey's post hoc test. Statistically significant differences were noted when $p < 0.05$. Statistical analyses were determined using Prism v8.4.3 Graphs were generated using Prism v8.4.3 (GraphPad, San Diego, CA).

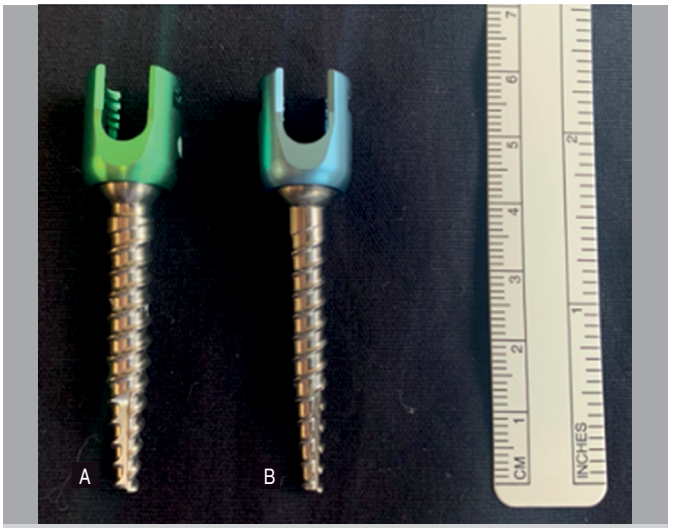

Figure 1. Photo of SpineGuard/Zavation Dynamic Surgical Guidance Z-Direct screw of and (A) 6.5 mm and (B) 5.5 mm outer diameter.

RESULTS

Pilot hole and tapping have been previously reported to influence the screw pullout strength. To evaluate the influence of pilot hole preparation and techniques, screws without pilot hole, without tapping, with undertapping and line to line tapping were inserted. The results of the 5.5 mm and 6.5 mm screws pullout strength according to the experimental groups are illustrated in the Figures 2 and 3.

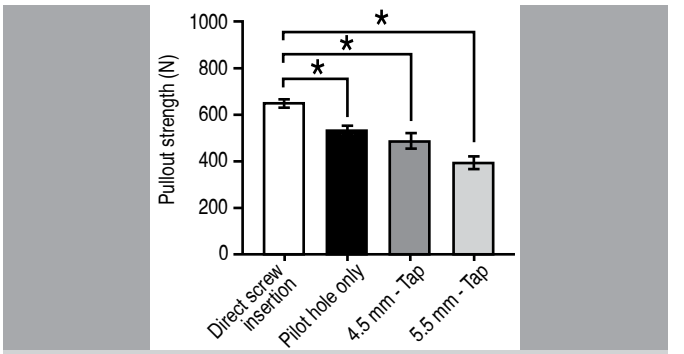

Figure 2. Mean maximal pullout strength of 5.5 mm SpineGuard / Zavation screw inserted into polyurethane blocks.
The asterisks (*) indicate statistical difference.

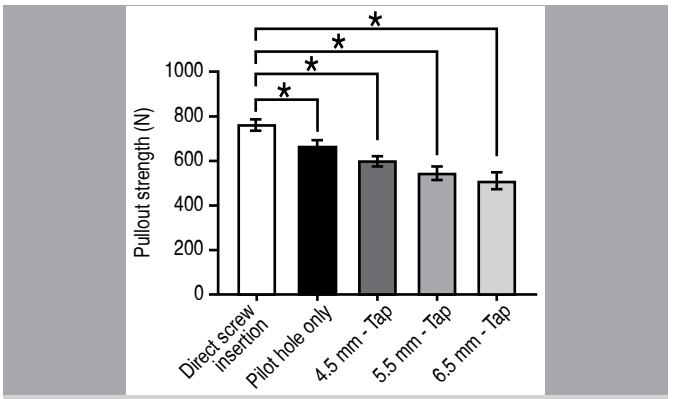

Figure 3. Mean maximal pullout strength of 6.5 mm SpineGuard/ Zavation screw inserted into polyurethane blocks.
The asterisks (*) indicate statistical difference.

The mean pullout strength for 5.5 mm and 6.5 mm screws inserted directly into the blocks without pilot hole or tapping were statistically higher, when compared to the other experimental groups ($p < 0.05$). As of note, we detected a 21% increase in the pullout strength of the 5.5 mm DSG screw during its direct insertion, when compared to the insertion with the use of pilot hole only. This increase was even higher when the direct insertion was compared to the other experimental groups; 33% increase versus 4.5 mm tapping and 65% versus 5.5 mm tapping (Figure 2). With regards to the 6.5 mm DSG screw, we detected a 15% increase in the pullout strength during its direct insertion, when compared to the insertion with the use of pilot hole only; 27% increase versus 4.5 mm tapping; 40% versus 5.5 mm tapping; and 49% versus 6.5 mm tapping (Figure 3). An increase of screw pullout strength was observed from the experimental groups using line to line tapping to the experimental group, in which the screws were inserted without pilot hole.

DISCUSSION

Our *in vitro* findings support the hypothesis that SpineGuard/Zavation screw has higher pullout strength after its insertion and tapping directly into the block without pilot hole. Higher pullout strength of DSG screw was recorded after its direct insertion into the polyurethane blocks compared with insertion with pilot hole, undertapping or line-to-line tapping.

Since the initial report on the use of pedicle screw for spine fixation, there has been a permanent improvement of this modality of spinal fixation, that is widely used to treat fractures, degenerative disease, tumor, deformities and spinal stability.[6-9] Pedicle screws continue to be studied to improve its locking mechanism in fixation system components, biomechanical screw performance and screw accuracy.[10] The main biomechanical requirements of pedicle screw are resistance to cantilever loads (loads oriented perpendicular to the long axis of screw as bending strength) and pullout resistance.

The bending strength depends on the material and it is proportional to screw core diameter.[11-12] The strength increases exponentially, it is proportional to the cube of screw core diameter, therefore the largest screw diameter allowed by the bony local anatomy should be used to minimized the likelihood of screw failure.[13-18]

Pullout resistance of the pedicle screw is influenced by bone mineral density,[5] screw geometry and insertion technique employed by the surgeon. Changes in screw design and optimization of pilot hole has been explored to improve the anchorage of the pedicle screws, as modifications of bone mineral density are not possible to be made acutely.[19] In bone with compromised BMD, augmentation of the screw with polymethylmethacrylate, calcium phosphate or hydroxyapatite, or modification to the screw diameter, length, thread design, expandable screws, fenestrated screw or change in screw trajectory has been attempted to increase the purchase of the implants.[19]

The usual and current surgical technique for pedicle screw insertion is a sequence of pilot hole followed by tapping and screw insertion.[19,20] The screw insertion is generally preceded by a pre-tapping using a smaller diameter than screw.[7] If the screw is inserted in untapped pilot hole, rates of misalignment may increase.[10] The holding power or pullout strength is influenced by the amount of bone inside the screw threads.[16] The perforation and tapping of the pilot hole result in additional trauma, increase operative time and decrease the screw pullout strength.[13] To eliminate these drawbacks, changes of screw designs were performed to eliminate drilling of the pilot hole and tapping.[14] Self-drilling and self-tapping screws were developed and used in spinal surgery for cervical plate fixation,[10] whose screw path is not so critical as pedicle screw. Pedicle screw should be inserted inside the pedicle wall that is surrounded by neural and other anatomical structures that can be injured.[15,16] Pedicles screws are typically placed using pilot holes and the trajectory of the pilot holes can be verified by pedicle sounding. Although pilot holes and tapping do not ensure that the screw will follow the pilot hole trajectory, for tapped pilot holes the risk of screw malposition is lower.[10]

Pullout strength is proportional to the volume of bone inside the screw thread,[13] bone implant-contact with increased area and density of bone inside and outside the screw thread is promoted by self-drilling screw as the DSG screw. However, screw pullout strength depends also on changes induced in bone by insertion trauma, reaction of bone to implant and resorption and remodeling as a result of healing.[15] Silva et al. reported increased implant-bone contact in vivo after screws inserted in pilot holes smaller than the screw internal diameter.[16] The highest pull-out strength of the direct screw insertion technique can be explained by a higher amount of bone squeezed at the bone-implant interface contact. Furthermore, *in vivo* studies may be required to confirm these findings.

The limitation of the study related to the used experimental model should be considered. Pullout strength test may not be commonly seen in a clinical setting, but its simplicity and reproducibility allow it to be considered as the most efficient method to compare screw anchorage within the bone.[13,15,16] Axial pullout test is easy to perform, reproducible and is accepted as a good predictor of the mechanical performance of the screw. Yet, pedicles screws are subjected to a complex mechanically demanding situation represented by an association of twisting, bending and pullout force[17,18]. Most of the time, pedicle screws fail by cyclic loading rather one-time pullout. Screw pullout strength does not represent the only mechanism of screw failure, but it still reflects the magnitude of screw anchorage purchase.[18]

Clinical applications

The DSG screw combines the characteristics that have been desired for pedicle screws, combining great resistance to pullout and improved positioning accuracy. However, only after the use of DSG screw in clinical settings and evaluation of the outcomes, the true benefits of DSG screw could be confirmed. Preliminarily, the results of the initial experimental evaluation showed advantages of the DSG screw. This component and its direct screw insertion technique provides better pullout strength. In addition, The DSG screw is a time saving approach compared to the traditional pedicle screw placement because screw insertion can be performed without pilot hole and tapping. The accuracy of the screw positioning is not compromised as all along the insertion as the DSG technology is providing guidance in real time to ensure a safe trajectory within the pedicle. And finally, the DSG screw, guided by the bipolar sensor on the tip of the screw, could also reduce intraoperative radiation. Preliminary reports of clinical use of this component was shown to be very successful (although not published yet).

CONCLUSION

The DSG screw and its direct screw insertion technique shows higher pullout strength in experimental *in vitro* study and it also has the advantage to improve accuracy of pedicle screw insertion with less radiation exposure. The DSG screw has the potential to change the way pedicle screw is inserted, for a faster and more accurate technique with less radiation. However, only after clinical use and evaluation of its cost benefit, its real advantage will be considered.

AUTHORS' CONTRIBUTIONS: Each author contributed individually and significantly to the development of this article. RPP: data collection, writing of the article, data analysis, project review, intellectual concept and article review; AZ: data collection; TC: study design; KG: study design; ACS: data analysis and project review; HLAD: data collection, writing of the article, data analysis, project review, intellectual concept and article review.

REFERENCES

1. Bolger C, Wigfield C. Image-guided surgery: applications to the cervical and thoracic spine and a review of the first 120 procedures. J Neurosurg. 2000;92(2 Suppl):175-80.
2. Bolger C, Carozzo C, Roger T, McEvoy L, Nagaria J, Vanacker G, Bourlion M. A preliminary study of reliability of impedance measurement to detect iatrogenic initial pedicle perforation (in the porcine model). Eur Spine J. 2006;15(3):316-20.
3. Chen LH, Tai CL, Lai PL, Lee DM, Tsai TT, Fu TS, et al. Pullout strength for cannulated pedicle screws with bone cement augmentation in severely osteoporotic bone: influences of radial hole and pilot hole tapping. Clin Biomech (Bristol, Avon). 2009;24(8):613-8.
4. Bolger C, Kelleher MO, McEvoy L, Brayda-Bruno M, Kaelin A, Lazennec JY, et al. Electrical conductivity measurement: a new technique to detect iatrogenic initial pedicle perforation. Eur Spine J. 2007;16(11):1919-24.
5. Chen SH, Mo Lin R, Chen HH, Tsai KJ. Biomechanical effects of polyaxial pedicle screw fixation on the lumbosacral segments with an anterior interbody cage support. BMC Musculoskelet Disord. 2007;8:28.
6. Williams J, Samdani A, Defino HLA, George K, Gaughan J, Betz R. Anticipation of vertebral pedicle breach through dynamic surgical guidance. Coluna/Columna. 2014;13(3):210-3.
7. Bohl DD, Basques BA, Golinvaux NS, Toy JO, Matheis EA, Bucklen BS, Grauer JN. Undertapping of Lumbar Pedicle Screws Can Result in Tapping With a Pitch That Differs From That of the Screw, Which Decreases Screw Pullout Force. Spine (Phila Pa 1976). 2015;40(12):E729-34.
8. Ovadia D, Korn A, Fishkin M, Steinberg DM, Wientroub S, Ofiram E. The contribution of an electronic conductivity device to the safety of pedicle screw insertion in scoliosis surgery. Spine (Phila Pa 1976). 2011;36(20):E1314-21.
9. Benzel EC. Biomechanics of Spine Stabilization. New York: Thieme; 2001.
10. Carmouche JJ, Molinari RW, Gerlinger T, Devine J, Patience T. Effects of pilot hole preparation technique on pedicle screw fixation in different regions of the osteoporotic thoracic and lumbar spine. J Neurosurg Spine. 2005;3(5):364-70.
11. Defino HLA, Rosa RC, Silva P, Shimano AC, Volpon JB, Paula FJA, et al. The effect of repetitive pilot-hole use on the insertion torque and pullout strength of vertebral system screws. Spine (Phila Pa 1976). 2009;34(9):871-6.
12. Lill CA, Schneider E, Goldhahn J, Haslemann A, Zeifang F. Mechanical performance of cylindrical and dual core pedicle screws in calf and human vertebrae. Arch.Orthop Trauma Surg. 2006;126(10):686-94.
13. Benzel EC. Implant-bone interfaces. In: Benzel EC. Biomechanics of Spinal Stabilization. New York: Thieme; 2001. p. 155-70.
14. Silva P, Rosa RC, Shimano AC, Paula FJA, Volpon JB, Defino HLA. Avaliação biomecânica da influência do macheamento e do desenho dos parafusos cervicais. Rev Bras Ortop. 2009;44(5):415-9.
15. Schatzker J, Sanderson R, Murnaghan JP. The holding power of orthopedic screws in vivo. Clin Orthop Relat Res. 1975;(108):115-26.
16. Silva P, Rosa RC, Shimano AC, Defino HLA. Effect of pilot hole on biomechanical and in vivo pedicle screw-bone interface. Eur Spine J. 2013;22(8):1829-36.
17. Erkan S, Hsu B, Wu C, Mehbod AA, Perl J, Transfeldt EE. Alignment of pedicle screws with pilot holes: can tapping improve screw trajectory in thoracic spines? Eur Spine J. 2010; 19(1):71-7.
18. Uhl RL. The biomechanics of screws. Orthop Rev. 1989;18(12):1302-7.
19. Shea TM, Laun J, Gonzalez-Blohm SA, Doulgeris JJ, Lee WE 3rd, Aghayev K, Vrionis FD. Designs and techniques that improve the pullout strength of pedicle screws in osteoporotic vertebrae: current status. Biomed Res Int. 2014;2014:748393.
20. **Defino HLA, Miranda RF, Pinheiro RP, Shimano AC. Influência do diâmetro e geometria no macheamento do orifício piloto nos parafusos pediculares. Coluna/Columna [online]. 2019;18(1):51-4.**

DOI: http://dx.doi.org/10.1590/1413-785220212904241563

PROSPECTIVE STUDY OF INJURIES OCCURRED DURING BRAZILIAN FOOTBALL CHAMPIONSHIP IN 2019

ESTUDO PROSPECTIVO DAS LESÕES ESPORTIVAS OCORRIDAS DURANTE O CAMPEONATO BRASILEIRO DE FUTEBOL EM 2019

Gustavo Gonçalves Arliani[1], Paulo Henrique Schmidt Lara[1], Gabriel Furlan Margato[1], Diogo Cristiano Netto[2], Moisés Cohen[1], Jorge Roberto Pagura[3]

1. Sports Traumatology Center, Escola Paulista de Medicina, São Paulo, SP, Brazil.
2. Brazilian Football Confederation, Rio de Janeiro, RJ, Brazil.
3. ABC Medical School (FMABC), Santo André, SP, Brazil.

ABSTRACT

Objective: To determine the incidence and risk factors for injuries that occurred during the matches of the Brazilian Football Championship. Methods: A prospective study was carried out with the collection of data referring to injuries that occurred during the 2019 Brazilian Football Championship. The injuries were recorded by the responsible physician of each team, through an online injury mapping system. Results: Among the 645 athletes who were included in the study, 214 (33.2%) of the players had at least one injury during the tournament. In total, 257 injuries were recorded during the Brazilian Championship, with an average of 0.68 injuries per game. 59.1% of the injured athletes were over 26 years old. The most common type of injury was muscle strain (37.7%) and forwards were the most affected (33.6%). Conclusion: Muscle injuries were the most frequent in the tournament, with the thigh muscles being the most affected. Most of the affected players were over 26 years old, there were 20.5 injuries for every 1000 hours of play and the incidence of injuries was approximately 33%, with attackers being the most affected (33.6%). ***Level of Evidence III, Study of nonconsecutive patients; without consistently applied reference "gold" standard.***

Keywords: Athlete. Football. Athletic Injuries.

RESUMO

Objetivo: Determinar a incidência e fatores de risco para as lesões ocorridas durante as partidas do Campeonato Brasileiro de Futebol. Métodos: Realizou-se um estudo prospectivo com coleta dos dados referentes às lesões ocorridas durante o Campeonato Brasileiro de Futebol de 2019. O registro das lesões foi realizado pelo médico responsável de cada equipe, por meio de um sistema online de mapeamento de lesões. Resultados: Dentre os 645 atletas que foram incluídos no estudo, 214 (33,2%) dos jogadores apresentaram pelo menos uma lesão durante o torneio. No total, foram registradas 257 lesões durante o Campeonato Brasileiro, com média de 0,68 lesões por partida. 59,1% dos atletas lesionados tinham mais de 26 anos. O tipo de lesão mais comum foi o estiramento muscular (37,7%) e os atacantes foram os mais acometidos (33,6%). Conclusão: Lesões musculares foram as mais frequentes no torneio, sendo a musculatura da coxa a mais acometida. A maioria dos jogadores afetados tinham mais de 26 anos, houve 20,5 lesões para cada 1000 horas de jogo e a incidência de lesões foi de aproximadamente 33%, com os atacantes sendo os mais afetados (33,6%). ***Nível de Evidência III, Estudo de pacientes não consecutivos; sem padrão de referência "ouro" aplicado uniformemente.***

Descritores: *Atleta. Futebol. Lesões Esportivas.*

Citation: Arliani GG, Lara PHS, Margato GF, Netto DC, Cohen M, Pagura JR. Prospective study of injuries occurred during Brazilian football championship in 2019. Acta Ortop Bras. [online]. 2021;29(4):207-210. Available from URL: http://www.scielo.br/aob.

INTRODUCTION

Soccer is the most practiced sport in Brazil and one of the most practiced worldwide.[1] When the sport is performed professionally, athletes are physically demanding, which can increase their predisposition to injuries.[1,2] The risk of injuries in soccer is relatively high when compared to other sports and activities, with incidence rates ranging from 15 to 70 injuries per 1000 hours of exposure in games.[1-9] The Brazilian soccer championship is one of the main championships in the world, with highly competitive athletes and clubs.[3] Due to the degree of national and world relevance, whether sporting or economic, excellence and maximum individual and collective performance of teams are sought in order to obtain the best results. Thus, there has been greater interest of clubs and confederations in physical preparation and improvement of preventive activities for injuries aimed at players.[4] Epidemiological studies on football injuries in Brazil are scarce. Brazil is a continental size country with a very different climate and conditions in relation to Europe and the United States, which could justify differences in patterns and risk factors for injuries.[1,10]

All authors declare no potential conflict of interest related to this article.

The study was conducted at Centro de Traumatologia do Esporte da Escola Paulista de Medicina.
Correspondence: Paulo Henrique Schmidt Lara. R. Estado de Israel 636, São Paulo, SP, Brazil, 04022001. phslara@gmail.com

Article received on 07/29/2020, approved on 09/24/2020.

Therefore, our study aimed to conduct a prospective assessment of injuries that occurred in professional soccer players of the Brazilian A Series championship in 2019, analyzing and correlating their characteristics with possible risk factors.

MATERIALS AND METHODS

This is a prospective study carried out with an electronic questionnaire previously developed and approved by the medical committee of the Brazilian Football Confederation, being used in the mapping of injuries in Brazilian soccer since 2016. The recording of injuries was performed by the physician responsible for each team, through an online injury mapping system available on the physician's portal of the Brazilian Football Confederation (CBF) (portaldomedico.cbf.com.br). The questionnaire was answered by the doctors of the teams that compete in the A series of the Brazilian soccer championship after each round of games in the 2019 championship. The questionnaire consisted of several questions about the match characteristics, the affected athlete and the injury. All athletes regularly enrolled in the 2019 A series Brazilian championship who participated in at least 1 game of the tournament were included in the study. Athletes enrolled by clubs that did not play in at least one game were excluded from the study. The definition of injury adopted was proposed by Fuller et al.[11] for the 2005 FIFA consensus, according to which an injury is "any physical complaint resulting from a football match, regardless of the need for medical assistance, attention or loss of time in football activities". To assess the risk of injury, we calculated the incidence of injury, which is expressed as the number of injuries per 1000 hours of exposure. The following formula was used to calculate exposure by correspondence: Exposure = number of matches in the championship × number of players participating in matches × match duration in minutes/60. To calculate the incidence of injuries, the following formula was used: Incidence = number of injuries in matches × 1000 hours/exposure time. Measures of central tendency and dispersion were expressed as means and standard deviation (SD) for continuous variables with symmetrical distribution, and as medians, minimum and maximum values for those with asymmetrical distribution. Categorical variables are expressed in their absolute and relative values. The estimate of difference between categorical variables was performed using the test for equality of two proportions and chi-square. The odds ratio (OR) was calculated to quantify the risk of injuries associated with some study variables. For all tests, a minimum significance level of 5% and a 95% confidence interval were considered.

This study was approved by the Research Ethics Committee of the Federal University of São Paulo/Escola Paulista de Medicina (567236616.3.0000.5505).

RESULTS

A total of 645 players participated in at least one match of the 2019 Brazilian championship and were included in this study. The tournament started in April and ended in December 2019, totaling 38 rounds, 380 matches and 20 participating professional teams. The average age of athletes participating in the championship was 26.1 years. Among the injured athletes, we found an average age of 26.9 years. Among the 645 athletes that were included in the study, 214 (33.2%) of players had some kind of injury during the tournament. In total, 257 injuries were reported, with an average of 0.68 injuries per match. The incidence of injuries in the Brazilian first division championship in 2019 was 20.5 injuries for every 1,000 hours of game. The relationship between injuries and the time the matches were played (morning, afternoon or evening) did not show significant differences, which can be seen in Table 1.

Table 1. Ratio of injuries × time of matches.

	With Injury		Without Injury		Total	
	N	%	N	%	N	%
Morning	10	3.9%	36	6.5%	46	5.7%
Afternoon	94	36.6%	171	30.8%	265	32.6%
Evening	153	59.5%	349	62.8%	502	61.7%
Total	257	31.6%	556	68.4%	813	100%

$p > 0.05$

Of the total number of injuries, 49.4% (127 injuries) occurred in players from the home team, however, we did not find a significant difference between injuries that occurred in the home and visiting teams, which can be seen in Table 2.

Table 2. Ratio of injuries × home/visiting team.

	With Injury		Without Injury		Total	
	N	%	N	%	N	%
Home	127	49.4%	280	50.4%	407	50.1 %
Visiting	130	50.6%	276	49.6%	406	49.9%
Total	257	31.6%	556	68.4%	813	100%

$p > 0.05$

Regarding the age of the injured players, we observed that most of them (59.1%) were over 26 years old. ($p < 0.001$) Regarding the position of injured athletes, we found a majority of forwards (33.6%), followed by midfielders (19%). With regard to the distance covered by the teams before the matches, most injuries occurred in matches played at home (50.8%). However, in away matches, most injuries occurred in games in which the visiting club traveled more than 800 kilometers (km) to the home club city (35%). The distribution of injuries in relation to the championship round in which they occurred is shown in Figure 1.

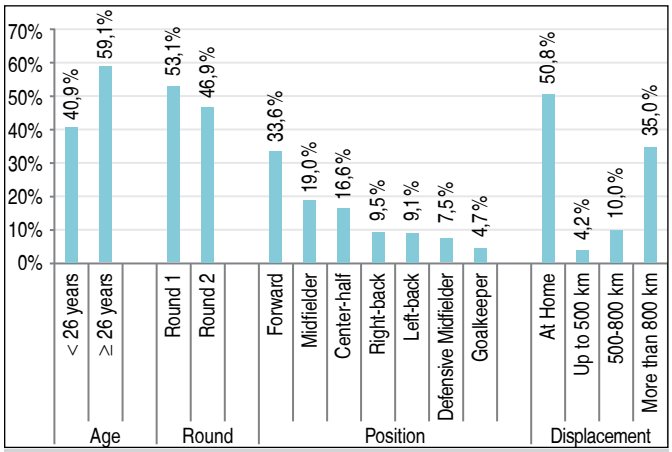

Figure 1. Distribution of variables × injured players.

Around 62% of the injuries (159) occurred without contact, with the thigh (40.5%), head (14%), ankle (11.7%) and knee (11.3%) being the most common body areas affected by injuries. Approximately 60% of injuries occurred in the midfield region, with the majority of injuries occurring in the last 15 minutes of the first half (23.6%) and in the central third of the second half of the match (21.7%), which can be seen in Figure 2.

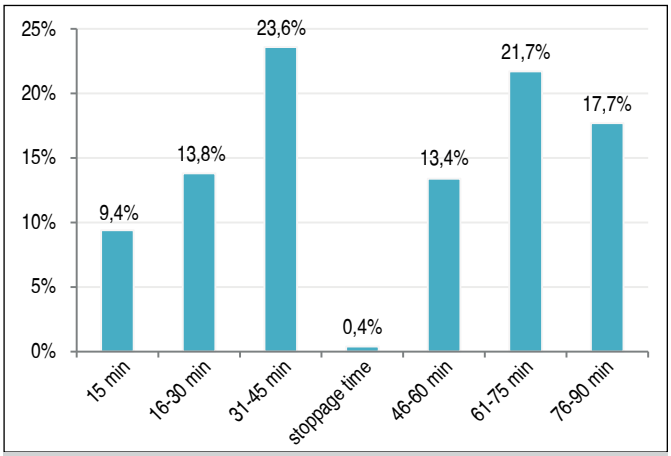

Figure 2. Distribution of the moment of injuries.

The most common types of injuries that occurred in the 2019 Brazilian championship were: muscle strains (37.7%), bruises (19.1%) and sprains (15.6%). Strain of the hamstring (15.6%) and adductor (10.9%) muscles were the two most common diagnoses. Recurrence of injury occurred in 8% of cases.

DISCUSSION

In the 2019 Brazilian championship, about a third of the athletes had some kind of injury during the championship, with an average of 0.68 injuries per match (20.5 injuries per 1000 hours of game). There were practically similar data between injuries in home and visiting teams. The most affected players were forwards and the most common injuries were thigh muscle strains. About half of the injuries occurred in matches at home, but injuries occurred away from home were more common in matches where there was a travel distance greater than 800 km.

The mean age of injured athletes in the study was 26.9 years, above that described in previous studies.[10,12] Almost 60% of patients were over 26 years of age. There was an average of 0.68 injuries per match, below the number reported in other studies, such as the one by Pedrinelli et al.[5] and Junge & Dvorak[13] who found 2.4 injuries per match. This difference may be due to the fact that our study evaluated a larger number of players and due to the longer championship model with more matches.

The incidence of injuries in the Brazilian championship in the first division in 2019 was 20.5 injuries for every 1,000 hours of game. Value that is within the variation found in the literature, which ranges from 15 to 70 injuries per 1,000 hours of game.[1-9] These values have this considerable variation due to differences in study designs, data collection methods and injury definitions.[14]

Most injuries occurred in the first round. There is a need for new studies that also assess this aspect, as it is expected that there would be a higher prevalence of injuries in the second round, due to the fact that most injuries are muscular, which are related to muscle fatigue, which in a general way is more common towards the end of the season.

Regarding the match period, there was no statistical difference in matches played in the morning, afternoon or evening. One could expect a higher incidence of injuries in the morning and afternoon, when there are usually higher temperatures, but this was not found in our study.

It was also evaluated whether there would be any difference in relation to the number of injuries and the fact that the team is home or visiting, but there was no statistical difference. A hypothesis suggested would be that there would be a higher incidence of injuries in the visiting team due to the displacement, opposing fans, worse sleep conditions and unusual grass. No previous study performed this assessment.

Forwards were the most affected, similar to previous studies,[1-4] but in other studies midfielders were the most affected.[15-17] One hypothesis for this difference is that these studies did not subdivide midfielders into defensive (holding or anchor) and attacking midfielders.

The majority of injuries occurred in matches at home and in those that occurred away from home, the majority occurred in matches where more than 800 km were covered. In the study by Bengtsson et al.[18] that evaluated 14 consecutive seasons of UEFA clubs there was a greater number of injuries when there was less than three days of rest between matches. This may be related to the fact that there is a higher incidence of injuries in matches with displacements above 800 km, in which athletes have a shorter rest time between matches.

Only about 40% of injuries occurred after contact, a figure below previous studies in which 50-70% of injuries occurred after contact.[1,5-7] It is noteworthy that the most common injury in this study was muscle injury, which most often occurs without contact between the athletes, which would justify this decrease in the percentage of injuries that occurred after contact.

The thigh was the most affected site (40.5%), followed by the head (14%), which is similar to previous studies.[5,9,15,19-22] Because the two most common injuries were muscle strains of the hamstrings and adductors, the thigh was the site most affected by injuries in the present study.

60% of the injuries occurred in midfield, we did not find any study in the literature that evaluated this aspect. This is expected, since most of the time the ball is in play it is in midfield and with that there is a higher percentage of injuries in this field region.

In our study, the majority (23.6%) of injuries occurred in the final 15 minutes of the first half, followed by the central third of the second half (21.7%), similar to what was found in our previous study,[1] but different from studies in which the majority of injuries occurred in the final 30 minutes of the game.[5,6]

The most common type of injury was muscle strain (37.7%), with the hamstring (15.6%) and adductor (10.9%) muscles being the most affected, which is similar to several studies previously carried out that found the same results.[1-4,9] In the study by Ekstrand et al.,[23] which evaluated 2299 players from European clubs between 2001 and 2009, about a third of the injuries were muscle injuries, and among these, hamstring muscle injuries were the most common, as in our study. Junge & Dvořák[24] assessed injuries that occurred during the 2014 World Cup in Brazil and the most common injury was muscle injury in the thigh and the authors recommended interventions to prevent non-contact lower limb injuries, which should be part of the soccer clubs' training routine.

A study limitation is the possibility of information bias, as it may have been modified or even omitted by the clubs' physicians. In addition, the study only assessed acute injuries that occurred during matches and did not assess injuries sustained during training and non-sport-related illnesses. Another limitation is that the exposure time was calculated based on 22 players and 90 minutes per match. A more accurate method would be to consider the stoppage time or actual duration of each match and the number of minutes of exposure for each individual player. The information obtained in this study is important in preventing new injuries in soccer. The data

will allow the medical teams of clubs and federations to develop preventive programs to reduce the incidence of injuries in soccer.

CONCLUSION

Muscle injuries were the most frequent in the tournament, with the majority affecting the forwards and thigh muscles. The majority of affected players were over the age of 26, there were 20.5 injuries for every 1,000 hours of game and the incidence of injuries was approximately 33%.

ACKNOWLEDGMENTS

We would like to thank the Brazilian Football Confederation and the physicians of the A-series teams who assisted in providing data for the production of this study.

AUTHORS' CONTRIBUTION: Each author contributed individually and significantly to the development of this article. GGA: Substantial contribution to the study design, writing and final approval; PHSL: writing and final approval; GFM: substantial contribution to the study analysis, writing; DCN: substantial contribution to the study analysis; MC: substantial contribution to the study design and final approval; JRP: substantial contribution to the study design, writing and final approval.

REFERENCES

1. **Arliani GG, Lara PHS, Astur DC, Pedrinelli A, Pagura JR, Cohen M. Prospective evaluation of injuries ocurred during a professional soccer championship in 2016 in São Paulo, Brazil. Acta Ortop Bras. 2017;25(5):212-5.**
2. **Netto DC, Arliani GG, Thiele ES, Cat MNL, Cohen M, Pagura JR. Prospective evaluation of injuries occurred during the Brazilian Soccer Championship in 2016. Rev Bras Ortop. 2019;54(3):329-34.**
3. **Arliani GG, Lara PHS, Astur DC, Pedrinelli A, Pagura JR, Cohen M. Orthopaedics injuries in male professional football players in Brazil: a prospective comparison between two divisions. Muscles Ligaments Tendons J. 2018;7(3):524-31.**
4. **Moraes ER, Arliani GG, Lara PHS, Silva EHR, Pagura JR, Cohen M. Orthopedic injuries in men's professional soccer in Brazil: prospective comparison of two consecutive seasons 2017/2016. Acta Ortop Bras. 2018;26(5):338-41.**
5. Pedrinelli A, Cunha Filho GAR, Thiele ES, Kullak OP. Estudo epidemiológico das lesões no futebol profissional durante a Copa América de 2011, Argentina. Rev Bras Ortop. 2013;48(2):131-6.
6. Aoki H, O'Hata N, Kohno T, Morikawa T, Seki J. A 15-year prospective epidemiological account of acute traumatic injuries during official professional soccer league matches in Japan. Am J Sports Med. 2012;40(5):1006-14.
7. **Pangrazio O, Forriol F. Epidemiology of soccer players traumatic injuries during the 2015 America Cup. Muscles Ligaments Tendons J. 2016;6(1):124-30.**
8. **Smpokos E, Mourikis C, Theos C, Linardakis M. Injury prevalence and risk factors in a Greek team`s professional football (soccer) players: a three consecutive seasons survey. Res Sports Med. 2019;27(4):439-51.**
9. **Jones A, Jones G, Greig N, Bower P, Brown J, Hind K, Francis P. Epidemiology of injury in English Professional Football players: A cohort study. Phys Ther Sport. 2019;35:18-22.**
10. Cohen M, Abdalla RJ, Ejnisman B, Amaro JT. Lesões ortopédicas no futebol. Rev Bras Ortop. 1997;32(12):940-4.
11. Fuller CW, Ekstrand J, Junge A, Andersen TE, Bahr R, Dvorak J, et al. Consensus statement on injury definitions and data collection procedures in studies of football (soccer) injuries. Clin J Sport Med. 2006;16(2):97-106.
12. Fachina RJFG, Andrade MS, Silva FR, Waszczuk-Junior S, Montagner PC, Borin JP, Lira CAB. Descriptive epidemiology of injuries in a Brazilian premier league soccer team. Open Access J Sports Med. 2013;4:171-4.
13. Junge A, Dvorak J. Injury surveillance in the World Football Tournaments 1998-2012. Br J Sports Med. 2013;47(12):782-8.
14. Arliani GG, Belangero PS, Runco JL, Cohen M. The Brazilian Football Association (CBF) model for epidemiological studies on professional soccer player injuries. Clinics (Sao Paulo). 2011;66(10):1707-12.
15. Morgan BE, Oberlander MA. An examination of injuries in major league soccer. The inaugural season. Am J Sports Med. 2001;29(4):426-30.
16. Noya Salces J, Gómez-Carmona PM, Gracia-Marco L, Moliner-Urdiales D, Sillero-Quintana M. Epidemiology of injuries in First Division Spanish football. J Sports Sci. 2014;32(13):1263-70.
17. **Hwang-Bo K, Joo CH. Analysis of injury incidences in the Korea national men's soccer teams. J Exerc Rehabil. 2019;15(6):861-6.**
18. **Bengtsson H, Ekstrand J, Waldén M, Hägglund M. Muscle injury rate in professional football is higher in matches played within 5 days since the previous match: a 14-year prospective study with more than 130 000 match observations. Br J Sports Med. 2018;52(17):1116-22.**
19. Schmidt-Olsen S, Bünemann LK, Lade V, Brassøe JO. Soccer injuries of youth. Br J Sports Med. 1985;19(3):161-4.
20. McMaster WC, Walter M. Injuries in soccer. Am J Sports Med. 1978;6(6):354-7.
21. Ekstrand J, Nigg BM. Surface-related injuries in soccer. Sports Med. 1989;8(1):56-62.
22. Astur DC, Novaretti JV, Uehbe RK, Arliani GG, Moraes ER, Pochini AC, et al. Muscle injury: current perspectives and trends in Brazil. Rev Bras Ortop. 2014;49(6):573-80.
23. Ekstrand J, Hägglund M, Waldén M. Epidemiology of muscle injuries in professional football (soccer). Am J Sports Med. 2011;39(6):1226-32.
24. unge A, Dvořák J. Football injuries during the 2014 FIFA World Cup. Br J Sports Med. 2015;49(9):599-602.

DOI: http://dx.doi.org/10.1590/1413-785220212904235492

CLINICAL APPLICATION OF 3D PRINTING TECHNOLOGY FOR PREOPERATIVE PLANNING OF THUMB RECONSTRUCTION

APLICAÇÃO CLÍNICA DA TECNOLOGIA DE IMPRESSÃO 3D PARA PLANEJAMENTO PRÉ-OPERATÓRIO DE RECONSTRUÇÃO DE POLEGAR

Lin Xu[1], Jia Tan[2], Pingou Wei[1], Xiang Luo[3], Haitao Tan[1], Chaitanya Shamsunder Mudgal[4]

1. Guigang City People's Hospital, Department of Hand & Foot Microsurgery, Guigang, Guangxi, China.
2. Guangzhou Medical University First Clinical Medical College, Guangzhou, Guangdong, China.
3. Guangxi Clinical Research Center for Digital Medicine and 3D Printing, Guigang, Guangxi, China.
4. Massachusetts General Hospital, Department of Orthopaedic Surgery, Orthopaedic Hand & Upper Extremity Service, Boston, Massachusetts, United States.

ABSTRACT

Objective: This study aimed to explore the clinical application of preoperative precise design for 3D printing and thumb reconstruction, which could help manage the patients with thumb defect and achieve better function and appearance. Methods: This was a retrospective study of 20 patients who underwent the surgery of harvesting toe transplant and thumb reconstruction between January 2015 and December 2016. The 3D model of the thumb defect was created and printed. The dimensions of skin and bones from donor site were precisely designed as reference for surgical operation. The surgery was performed according to the model. Results: Perfect repair of defects was achieved with satisfying appearance and function. The reconstructed thumbs all survived (survival rate of 100%). Follow-up was 3-9 months. The maximum dorsiflexion was 8-30° and the maximum flexion was 38-58°. The two-point sensory discrimination was 9-11 mm. In total, 17 patients reposted "Excellent" satisfaction and three "Good", each for the reconstructed thumb and hand function, respectively. The satisfaction rate was 85%. Conclusion: Preoperative digital design and 3D printing according to the donor and recipient sites allowed a tailored operation. The operation was more precise, the appearance of the reconstructed thumb was good. ***Level of Evidence II, Retrospective Study***.

Keywords: Finger Injuries. Bone Transplantation. Reconstructive Surgical Procedures. Printing, Three-Dimensional. Computer-Aided Design.

RESUMO

Objetivo: Este estudo explorou a aplicação clínica do desenho pré-operatório preciso para impressão 3D e reconstrução do polegar, para ajudar no controle e melhorar função e aparência. Métodos: Estudo retrospectivo de 20 pacientes submetidos à cirurgia de colheita de transplante de dedo do pé e reconstrução do polegar entre janeiro de 2015 e dezembro de 2016. O modelo 3D do defeito do polegar foi confeccionado e impresso. As dimensões da pele e dos ossos da área doadora foram precisamente projetadas como referência para a operação cirúrgica, realizada de acordo com o modelo. Resultados: O reparo perfeito foi alcançado com aparência e função satisfatórias. Todos os polegares reconstruídos sobreviveram (taxa de sobrevivência de 100%). O acompanhamento foi de 3-9 meses. A dorsiflexão máxima foi de 8-30° e a flexão máxima foi de 38-58°. A discriminação sensorial de dois pontos foi de 9-11 mm. No total, 17 pacientes reportaram índice "Excelente" e três índice "Bom" cada para a função reconstruída do polegar e da mão, respectivamente. O índice de satisfação foi de 85%. Conclusão: O design digital pré-operatório e a impressão 3D de acordo com os locais doador e receptor permitiram uma operação customizada. A operação foi mais precisa, com bom aspecto. ***Nível de Evidência II, Estudo Retrospectivo.***

Descritores: *Traumatismos dos Dedos. Transplante Ósseo. Procedimentos Cirúrgicos Reconstrutivos. Impressão Tridimensional. Desenho Assistido por Computador.*

Citation: Xu L, Tan J, Wei P, Luo X, Tan H, Mudgal CS. Clinical application of 3D printing technology for preoperative planning of thumb reconstruction. Acta Ortop Bras. [online]. 2021;29(4):211-218. Available from URL: http://www.scielo.br/aob.

INTRODUCTION

Thumb trauma can lead to dramatic effects on the functions of the hand, witch shows an urgent need for a more rational and standardized surgical approach to achieve thumb reconstruction with the best function and appearance, high safety and effectiveness profiles, and with minimal donor site injury.[1]The applications of 3D printing in medicine include preoperative planning, simulation of fracture reduction, prosthesis customization, tissue engineering, doctor patient communication, and

All authors declare no potential conflict of interest related to this article.

The study was conducted at Guangxi Clinical Research Center for Digital Medicine and 3D Printing, Guigang City People's Hospital.
Correspondence: Haitao Tan. Department of Hand & Foot Microsurgery, Guigang City People's Hospital, Guigang 537100, Guangxi, China. tanhaitao99@hotmail.com

Article received on 24/03/2020, approved on 24/09/2020.

medical education.[2] As for thumb reconstruction surgery, surgical models and customized prosthesis can be made by 3D printing according to the specific condition of the patient, which not only simplify the surgical operation and reduce the operation time, but also enhance the surgical quality and therapeutic effect with reduced surgical risk.[2-6]

This study aimed to explore the clinical application of preoperative precise design for 3D printing and thumb reconstruction. The results could help manage the patients with thumb defect and achieve better function and appearance.

MATERIALS AND METHODS

Study design and patients

This was a retrospective study of 20 patients who underwent the surgery of harvesting toe transplant and for thumb reconstruction between January 2015 and December 2016. The study was approved by ethics committee of our hospital and has been performed in accordance with the ethical standards as laid down in the 1964 Declaration of Helsinki and its later amendments or comparable ethical standards. An informed consent form was signed by each patient.

The inclusion criteria were: 1) the metacarpophalangeal joint (MP) of the injured thumb was good; 2) the thumb injury occurred within 2 years; 3) third degree thumb defect, including IIIa (proximal phalanx defect) and IIIb (loss of proximal phalanx and across the base). The exclusion criteria were: 1) chronic osteomyelitis, bone and joint tuberculosis, synovitis, and diabetes mellitus; 2) defect of the first metacarpophalangeal joint of the injured thumb; or 3) both thumb were injured.[7]

Preoperative planning and digital design

Figure 1 presents the imaging workflow. Preoperative 64-row dual source spiral computed tomography (CT) scanning (SIEMENS, Erlangen, Germany) was performed for donor foot and injured hands. Feet CT angiography (CTA) was also performed to reconstruct the foot skeleton and blood vessels, so that the relationship between the bone and the first dorsal metatarsal artery was determined before operation.[8] Iohexol (370 mg I/ml) was injected through the median cubital vein and the hands were scanned using 64-row dual source spiral CT at 120 kV and 110 mA, thickness of 1 mm, matrix of 512×512, and scanning time of 200 ms. The CT images of donor foot and hands were imported into the Mimics 14.0 software as DICOM format, and converted into 3D images of bone and soft tissues. Given the symmetrical characteristics of hands and feet, the mirror image of the healthy thumb was created by using the Cutwith Curve software, and overlapped with the injured thumb using the Move and Rotate tools. The accurate size, area, and shape of the thumb defect could be accurately calculated, and segmented using the Cut with Curve tools. The segmented part was the real defect region. The study was approved by ethics committee of our hospital and has been performed in accordance with The ethical standards as laid down in the 1964 Declaration of Helsinki and its later amendments or comparable ethical standards. An informed consent form was signed by each patient.

3D printing and simulation operation

The thumb reconstruction strategy was determined according to the thumb defect type. The model of the defect region created from the mirror image was moved to the donor foot site by using the Move and Rotate tools. The projection of the model on the donor sites was used as the operation markers, but 0.2 and 0.3 mm larger. The incision to expose the flap's blood vessel was made according to the preoperative CT post-processed CTA image with volume rendering. Similarly, the length of the vascular pedicle was calculated according to the thumb defect.

The model of reconstructed skin and tissue was printed using a 3D printer, and the length as well as the size of skin and bone from the donor site could be accurately calculated, which could be used for donor tissue dissection and designed individually before operation. The whole process was more standardized and accurate, with more real-like appearance and minimized donor injury.

The individualized 3D model was created by simulation reconstruction through the Mimics medical software. The model was then imported into the makew-are software to adjust its position and inclination angle, and exported as x3g format for SD disk saving. Then, the models of bone and skin soft tissues were printed using a MakerBot 3D printer (MakerBot, New York City, NY, USA). Adhesive plaster was used to apply to the surface of the model, and used as template for donor site operation after cutting into pieces.

The adhesive plaster applied to the surface of the 3D model was peeled apart. The peeled adhesive plaster was applied to the donor site, and the line was made according to the adhesive plaster, which was used as marker to indicate the size and shape of the flap.

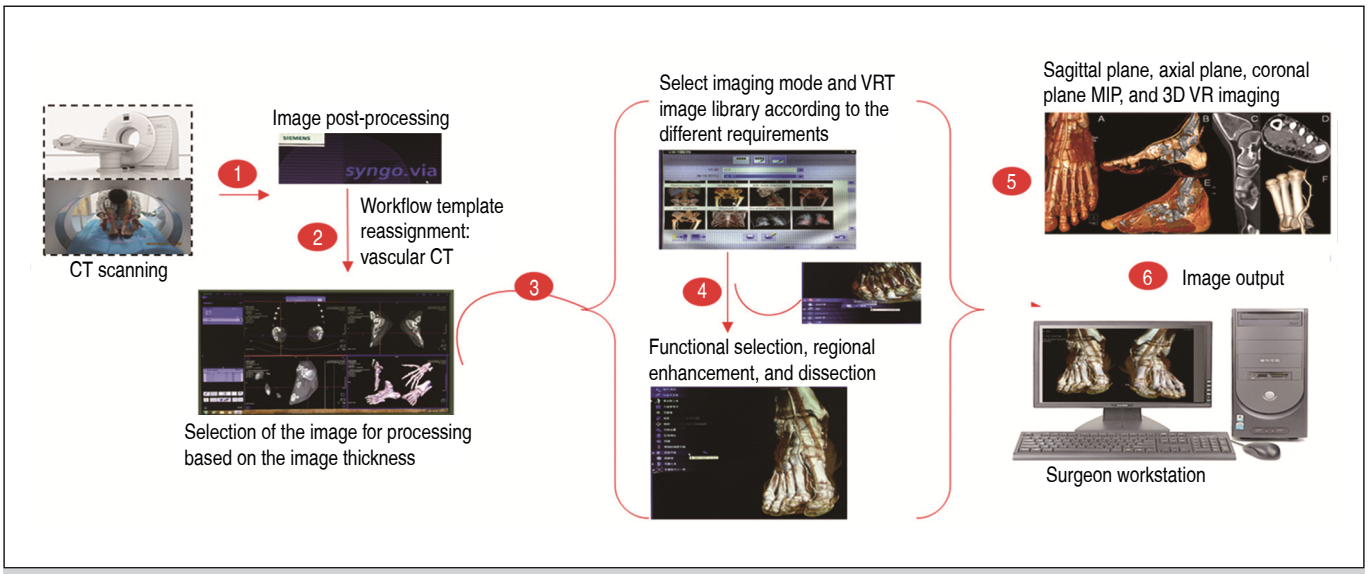

Figure 1. Imaging workflow.

Surgical considerations

The surgical mode was selected based on the thumb defect: 1) toe paratelum or toenail flap reconstruction for I° and II° defects, and toenail flap or second toe reconstruction for III° defect; 2) toe fibular ventral skin flap reconstruction for thumb pulp defect; 3) toe distal with nail flap reconstruction for degloving injuries of the thumb skin; 4) reconstruction of the second toe of the dorsum pedis flap with fibular helm and metatarsophalangeal joint, or reconstruction of the second toe and tendon tissue flap combined with metatarsophalangeal joint reconstruction for IV° defect; and 5) reconstructing of contralateral second toe with the rhomboid dorsalis pedis flap and metatarsophalangeal joint for V° and VI° defects. The size and length of the thumb defect were confirmed by preoperative digital imaging and 3D printing and projected to the donor size. The precise incision not only facilitated reconstruction and appearance improvement, but also helped the functional recovery. The donor toe paratelum phalanx with suitable length was fixed with the basal area of the phalangette for the distal phalanx of finger defect with intact distal interphalangeal joint. If the distal interphalangeal joint was injured, the suitable length of the paratelum phalanx of second toe was kept fixing with the middle phalanx of finger. The distal interphalangeal joint of hand was reconstructed with the distal interphalangeal joint of toe. The bone fixation was mainly dependent on wire cross strapping or Kirschner wire.

The design circumference of the flap pedicle from the harvested toe had to be 15-20% larger than that of the actual defect, in order to avoid skin suture tension, prevent flap atrophy, and maintain blood supply. The length of the dissociated vascular pedicle had to be appropriate; too short pedicle could lead to increased tension of vascular anastomosis; too long pedicle could result in the zigzagging blood vessels and poor blood supply.[9]

Surgery

The incision mark was made on the great toe based on the preoperative design strategy according to the skin, nerve, blood vessel, and tendon defects on the thumb. The edematous nerves and inflammatory necrotic vascular bundles were also removed.[10]

The skin and subcutaneous tissue were opened according to the pre-designed marker. The first dorsal metatarsal artery, dorsalis pedis artery, great saphenous vein of dorsal foot, dorsal venous arch of foot, and dorsal vein of second toe were dissected. The osteotomy was conducted according to the length of the 3D printed model. After the great toe flap was dissected, the bone was fixed with Kirschner wire of 1.0 mm diameter. The extensor digitorum longus tendon and the flexor digitorum longus tendon were sutured.[11] Anastomosis of nerves and vessels was conducted under the microscope. If the tension was excessive, a full-dimension skin flap on the same side thigh was obtained to cover the incision and fixation.[12]

Postoperative management

Conventional treatment and nursing after amputated finger replantation and thumb reconstruction were performed including warm preservation, anti-convulsion, anti-coagulation, and anti-infection.

A monthly review at our hospital was suggested for all patients, and the follow-up period lasted 3-9 months (6 months in average). The length, thickness, appearance, flexion and extension, strength of grasping and griping, and sensory evaluation such as two-point sensory discrimination and Michigan Hand Outcomes Questionnaire (MHQ)[13] scores were performed.

Statistical analysis

Continuous data were tested for normal distribution using the Kolmogorov-Smirnov test. Normally distributed continuous data were presented as mean ± standard deviation and analyzed using the paired t test. Non-normally distributed data were presented as median (range) and analyzed using the Wilcoxon test. Categorical data were presented as frequencies and analyze d using the Fisher exact test. All analyses were conducted using SPSS 16.0 (IBM, Armonk, NY, USA). Two-sided P-values <0.05 were considered statistically significant.

RESULTS

Characteristics of the patients

In total, 13 men and 7 women participated in this study. Their age ranged between 2 and 45 years old. The causes of injury included machinery accident for 12 patients, plate planer injury for three patients, and chainsaw injury for five patients (Table 1).

Table 1. Characteristics of the patients

Case	Age (years)	Degree of thumb defect	Defect of the first web	Length of required thumb (mm)	Width of healthy toe (mm)	Thickness of healthy digital pulp (mm)
1	22	I	Yes	32	16	15
2	23	II	Yes	31	15	14
3	29	IIIa	No	42	18	17
4	2	IIIa	No	22	12	12
5	34	IIIb	Yes	41	16	14
6	45	IIIa	No	37	17	15
7	28	IIIb	Yes	38	17	16
8	31	IIIa	Yes	31	13	12
9	44	II	No	32	14	14
10	27	IIIa	No	33	13	13
11	11	IIIa	Yes	31	14	13
12	38	IIIb	No	41	17	15
13	39	I	Yes	35	16	14
14	41	IIIa	No	44	17	15
15	29	IIIb	No	46	18	16
16	30	IIIa	Yes	46	17	15
17	33	II	No	32	14	14
18	29	IIIa	No	37	15	13
19	27	IIIa	Yes	38	16	13
20	21	IIIb	Yes	39	16	14

3D models

The models of defect tissues and bones were 3D-printed for 20 patients with thumb reconstruction. Perfect repair of defects was achieved with satisfying appearance and function (Table 2). The reconstructed thumbs all survived (survival rate of 100%).

Table 2. Post-surgical outcomes of 20 thumb reconstructions using a 3D-printed model.

Case	Age (years)	Time of operation (h)	Length of reconstructed thumb (mm)	Width of nail (mm)	Thickness of digital pulp (mm)	Satisfaction
1	22	6.1	33	16	10	Excellent
2	23	6.2	30	15	9	Excellent
3	29	6,0	41	17	10	Excellent
4	2	5.9	25	13	8	Good
5	34	6.4	40	18	10	Excellent
6	45	6.1	36	16	11	Excellent
7	28	6.7	37	16	9	Excellent
8	31	6.9	32	15	10	Good
9	44	7.2	33	15	9	Excellent
10	27	6.8	32	15	10	Excellent
11	11	6.1	31	15	9	Excellent
12	38	6.7	40	18	10	Excellent
13	39	6.9	36	16	8	Excellent
14	41	7.2	43	18	10	Excellent
15	29	6.8	44	19	11	Good
16	30	6.1	45	19	9	Excellent
17	33	6.7	31	14	10	Excellent
18	29	6.9	35	14	9	Excellent
19	27	7.2	36	16	9	Excellent
20	21	6.8	37	15	9	Excellent

Follow-up

The postoperative follow-up was conducted for 3-9 months (6 months in average). The length of reconstructed thumb ranged 25-45 mm, with a thickness of 8-11 mm. The maximum dorsiflexion was 8-30° and the maximum flexion was 38-58°. The two-point sensory discrimination was 9-11 mm. The Michigan Hand Outcomes Questionnaire (MHQ) was performed, and the general score was 25.0-69.1%, the work score was 25-45%, the pain score was 38-73%, the appearance score was 17.1-31.1%, the final score was 12.5-47.0%, and the Michigan Hand Outcome score was 26-45%. The strength assessment showed that the key inch was 31-56% and the grip power was 31-54%. The results of functional evaluation for all reconstructed thumbs were satisfactory, with 'Excellent' 17 cases and 'Good' 3 cases. The satisfaction rate was 85% (Tables 2, 3, and 4).

Table 3. Post-surgical functions of 20 thumb reconstructions using a 3D-printed model.

Case	Age (years)	Gilbert's classification of FDMA	Function of thumb opposing (cm)	Mobility of MP (angle of extension and flexion)	Two-point discrimination (mm)	Condition of using hand
1	22	Ia	0.9 (<1.0)	Extension 30˚, flexion 50˚	9	Excellent
2	23	IIb	1.5 (1.0-2.0)	Extension 21˚, flexion 55˚	10	Excellent
3	29	IIa	0.9 (<1.0)	Extension 20˚, flexion 38˚	11	Excellent
4	2	IIa	0.8 (<1.0)	Extension 11˚, flexion 40˚	9	Good
5	34	IIb	1.1 (1.0-2.0)	Extension 14˚, flexion 45˚	10	Excellent
6	45	IIa	1.5 (1.0-2.0)	Extension 10˚, flexion 58˚	11	Excellent
7	28	IIb	0.9 (<1.0)	Extension 8˚, flexion 40˚	9	Excellent
8	31	Ib	1.4 (1.0-2.0)	Extension 12˚, flexion 45˚	10	Good
9	44	Ia	0.5 (<1.0)	Extension 15˚, flexion 55˚	11	Excellent
10	27	IIa	0.0(<1.0)	Extension 28˚, flexion 40˚	9	Excellent
11	11	IIb	0.7 (<1.0)	Extension 30˚, flexion 45˚	10	Excellent
12	38	Ia	0.9 (<1.0)	Extension 10˚, flexion 50˚	11	Excellent
13	39	Ib	1.3 (1.0-2.0)	Extension 5˚, flexion 58˚	9	Excellent
14	41	IIb	1.5 (1.0-2.0)	Extension 10˚, flexion 40˚	10	Excellent
15	29	IIb	1.4 (1.0-2.0)	Extension 11˚, flexion 45˚	9	Good
16	30	IIa	1.3 (1.0-2.0)	Extension 7˚, flexion 55˚	9	Excellent
17	33	IIb	1.2 (1.0-2.0)	Extension 13˚, flexion 57˚	10	Excellent
18	29	Ia	1.1 (1.0-2.0)	Extension 20˚, flexion 38˚	11	Excellent
19	27	IIa	0.7 (<1.0)	Extension 27˚, flexion 55˚	9	Excellent
20	21	Ib	0.5 (<1.0)	Extension 18˚, flexion 45˚	9	Excellent

Table 4. Michigan Hand Outcomes Questionnaire and strength assessment of 20 thumb reconstructions using a 3D-printed model.

Case	Gender	Fellow-up (months)	Michigan Hand Outcomes Questionnaire						Strength	
			General score (%)	Work score (%)	Pain score (%)	Appearance score (%)	Final score (%)	Michigan Hand Outcome Score (%)	Key pinch (%)	Grip power (%)
1	Male	6	25	25	50	18.8	16.7	26	45	39
2	Female	7	45	43	57	20.1	32.5	45	55	48
3	Male	9	66.2	44	64	20.1	32.9	43	43	35
4	Male	6	69.1	45	55	31.3	37.5	55	56	45
5	Male	7	40.1	34	52	22.4	20.4	32	55	43
6	Male	8	48.9	21	55	31.2	31.4	33	50	44
7	Male	6	52.4	29	58	29.1	30.1	37	51	48
8	Female	6	30.9	25	40	18.8	12,5	27	41	36
9	Male	8	33.2	37	41	27.1	18.4	29	41	32
10	Male	9	30.2	42	42	29.8	19.1	30	52	36
11	Male	6	37.7	44	38	27.4	21.8	32	43	42
12	Male	7	32.4	20	70	25.2	45.8	37	48	42
13	Female	6	36,4	38	73	27.3	44.3	39	50	46
14	Male	7	42.2	37	68	17.1	42.1	40	55	54
15	Male	9	42.9	26	64	19.1	47.2	44	48	32
16	Male	9	45.1	26	61	18.4	36.2	42	49	42
17	Male	6	45.0	37	57	25.2	28.1	40	41	49
18	Female	6	34.4	34	52	27.3	27.6	28	31	45
19	Male	6	45.2	42	61	17.1	32.7	29	39	31
20	Male	6	45.5	42	60	19.1	37.1	21	54	37

Typical cases

Case 1 was a 2-year-old boy, with distal phalanx complete amputation of right thumb. And Case 2 was an 11-year-old boy, with left thumb amputation. Both were injured by machine and performed replantation in emergency, that failed. Before toe transplantation, CTA was performed to obtain 3D information of the first dorsal metatarsal artery regarding to type, origin, route, and branches distribution. The whole picture of amputated thumb was created based on the other healthy hand through digital design, so that reconstruction model for amputated thumb was obtained. Then, reconstruction model was 3D-printed, and medical adhesive plaster was attached to 3D reconstruction model. Through that, first toe flap template was obtained by cutting medical adhesive plaster along 3D reconstruction model.

Both cases were used first toenail flap harvesting and transplantation for thumb reconstruction. The operations were conducted in accordance with preoperative designs (Figure 2, 4 and 5). Reconstructed thumbs of them survived with grade I wound healing and were follow-up regularly. Appearances of reconstructed thumbs were close to normal one 6 months after reconstruction. Grasp, holding, kneading, and thumb opposition were basically normal (Figure 3 and 6). The two-point sensory discrimination was 6 and 8 mm, respectively.

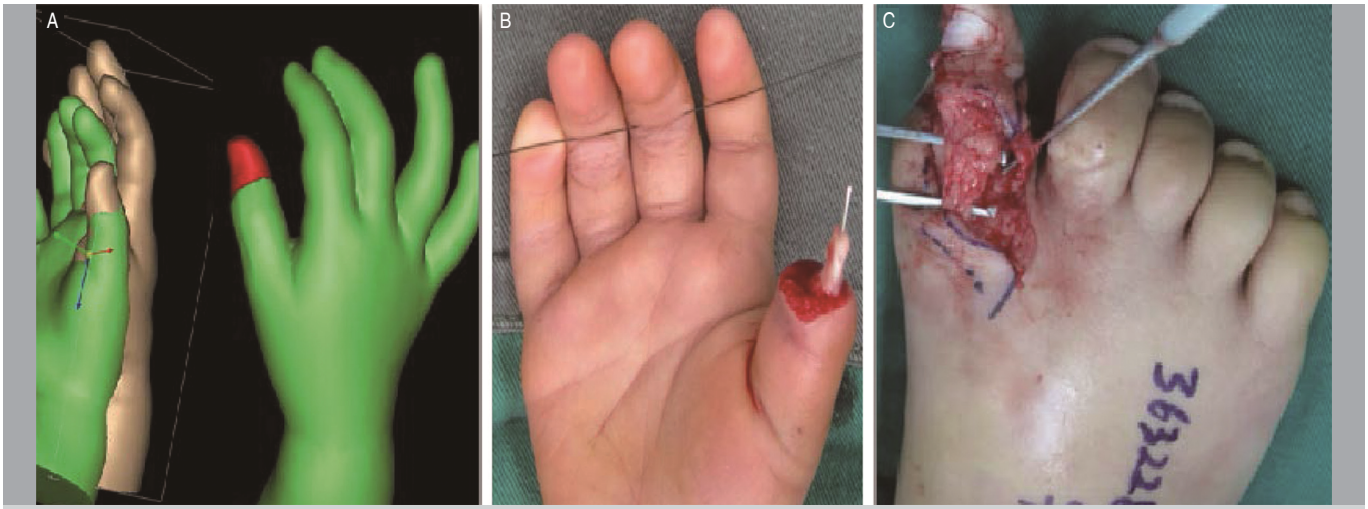

Figure 2. Reconstruction of the thumb tip by digital design and intraoperative operation. A: Digital design. B: Injured hand. C: Harvesting of the toe.

Figure 3. Six months after thumb reconstruction. A: Appearance comparison of the reconstructed thumb. B: Grasp function of the reconstructed thumb with interphalangeal joint flexion of about 90°. C: Donor area appearance.

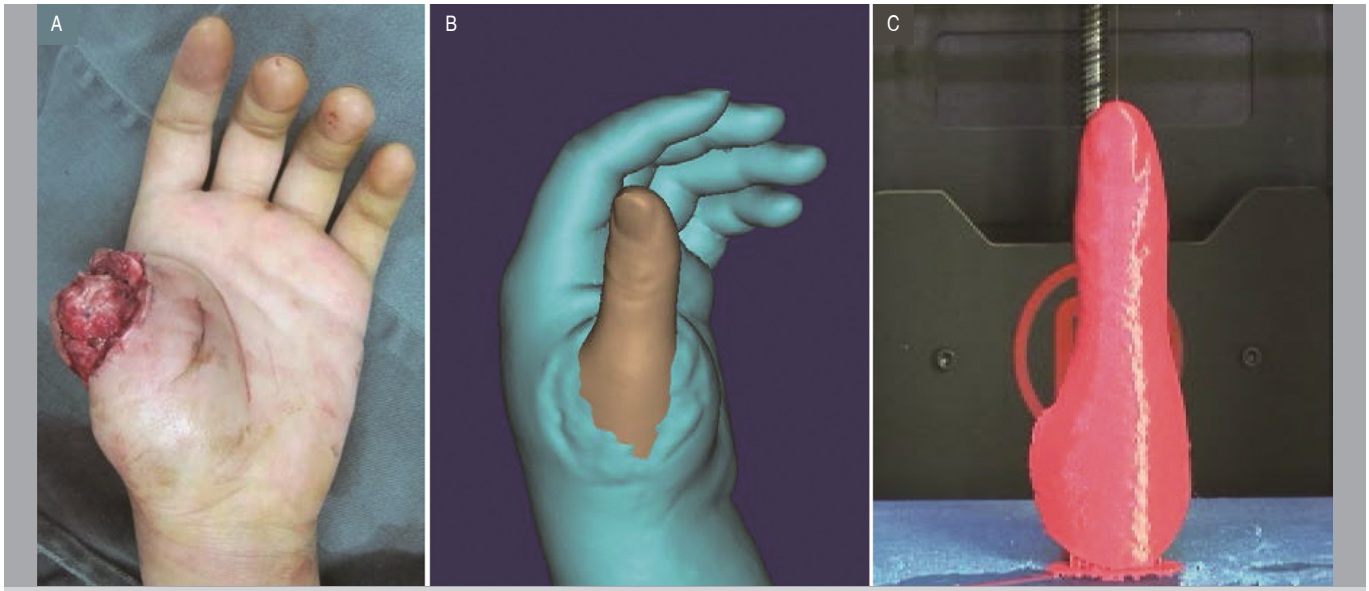

Figure 4. Preoperative design for thumb reconstruction. A: Left hand wound. B: Simulation of the reconstructed left thumb. C: Model printing.

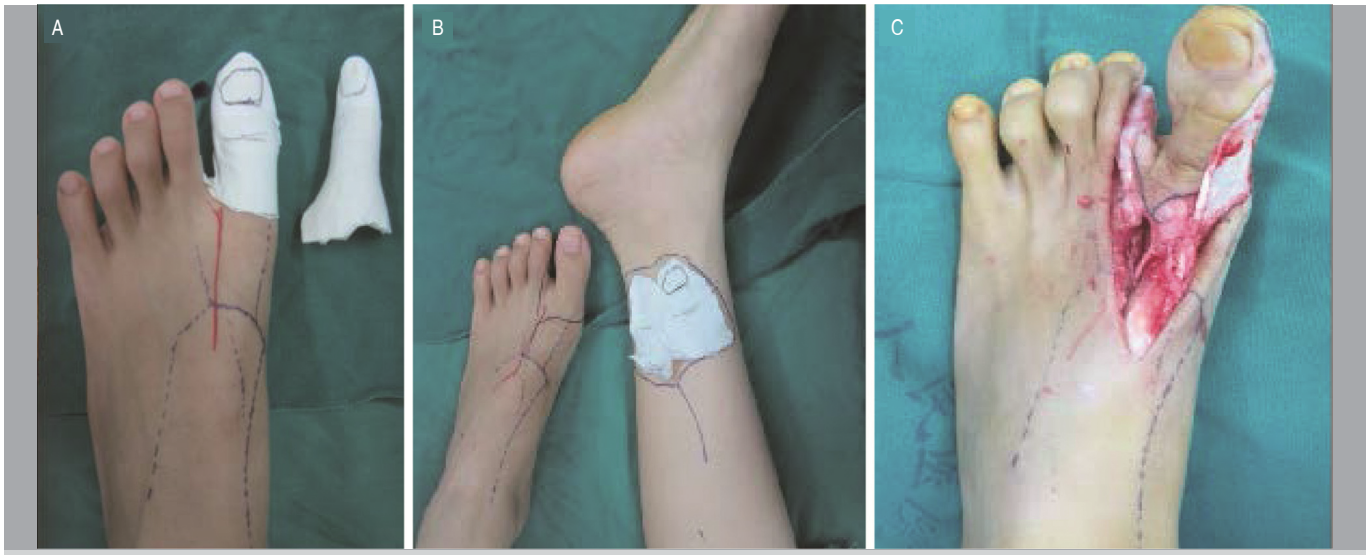

Figure 5. Operation for thumb reconstruction. A: Fabric design attached to the left food in order to mark the blood vessels and incisions. B: Fabric design attached to donor foot. C: Dissociated left great toe.

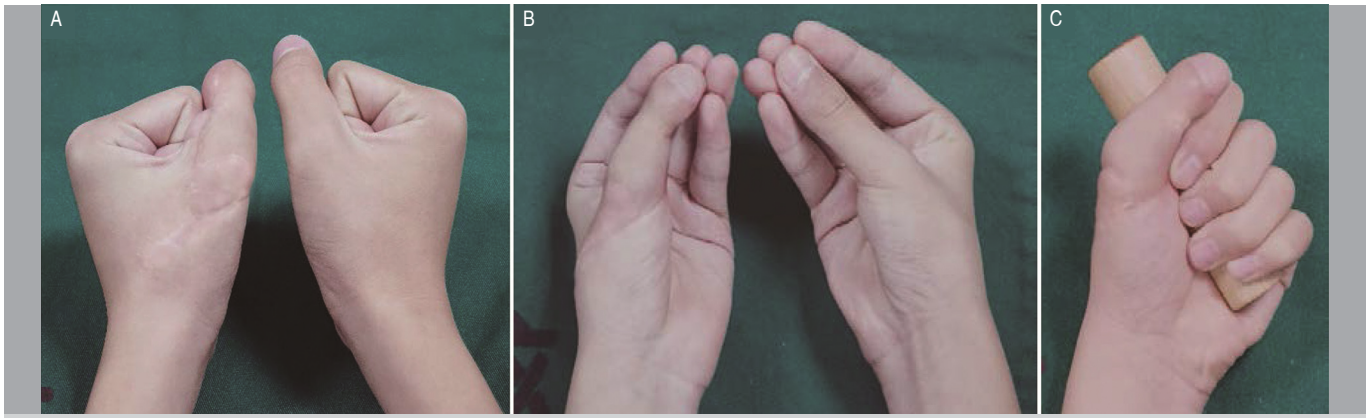

Figure 6. Six months after thumb reconstruction. A: Grip function of the two hands. B: Opposite function of the two hands. C: Holding function of the left hand.

DISCUSSION

3D printing has been suggested to potentially improve the outcomes of limb reconstruction.[2-6] This study aimed to explore the clinical application of preoperative precise design for 3D printing and thumb reconstruction. The results showed that preoperative digital design and 3D printing according to the donor and recipient sites allowed a tailored operation. The operation was more precise, the appearance of the reconstructed thumb was good, and the donor injury was minimal. The objectives of thumb reconstruction included the restoration of thumb length, strength, position, stability, mobility, sensitivity, and appearance.[14] Toe nail flap harvesting and transplantation for thumb reconstruction was firstly reported by Morrison in 1980 and successful, but 30% of the patients had foot dysfunction.[15] To overcome these disadvantages, computer-assisted design and 3D printing could provide novel options for individualized and precise hand surgery.[16-20] The advantages of these new technologies include: 1) precise positioning of surgical anatomy and location lesions; 2) preoperative simulation of operation and designing of surgical strategy; 3) intraoperative 3D real-time navigation; 4) determination of the extent of resection and surgical approach; and 5) simulation, teaching, and telemedicine.[21] These advantages are fully applicable to the reconstruction of thumb and finger defect.

3D printing technology could turn anatomical model from 2D to 3D, from plane to stereoscopy, and from static to dynamic. The preoperative observation of target site can be made by the surgeons to determine the optimal operation plan and the operation mode will eventually be changed from the traditional 'open-observe-operate' to 'observe-open-operate'.

The region of donor skin and soft tissue, and the size and length of bone can be accurately designed based on 3D-printed reconstructed model. The simulated reconstruction can be performed using a 3D medical software based on injured and healthy hands.[22] 3D printing improves the individualized and precise reconstruction strategy for thumb and finger defect and could decrease this risk because of better visualization and planning.

The good results in the present study were comparable to a study by Zang et al.[16] in five patients who underwent wrap-around flap design and second toe transplant to reconstruct a thumb. They showed excellent results in four patients and good results in one. Their success rate was 100%. Another study of four patients showed satisfactory reconstruction of the thumb using a donor toe after preoperative 3D-printed modeling of the surgical approach.[8] This study showed a success rate of 100% in 20 patients, with excellent or good appearance and function. These previous studies and ours suggest that this approach is promising for the planning of thumb reconstruction. Our conclusion is that based on rich experience and superb technique, digital preoperative planning and 3D printing can be used as an aid to reduce dependence on surgeons' experience and lower difficulty of some challenging operations. For example, size and shape of flap can be cut more accurately. Besides, side- injury of donor site can be reduced. From this aspect, 3D printing still has certain advantages in thumb reconstruction.

CONCLUSION

Our study is not without limitations. The number of patients was small and from a single center. There was no control group or randomization. Additional studies are necessary to determine the exact clinical value of this approach.

ACKNOWLEDGEMENTS

The study was supported by Guangxi digital medicine and 3D printing clinical medicine research centre construction (GuiKe AD17129017) and Capacity building of academician workstation of guigang people's hospital of guangxi (GuiKe AD17195042).

AUTHOR'S CONTRIBUTIONS: Each author contributed individually and significantly to the development of this article. LX and JT: carried out the studies, participated in data collection, and drafted the manuscript; XL: performed the statistical analysis and participated in its design; HT and CSM: helped to draft the manuscript. All authors read and approved the final manuscript.

REFERENCES

1. **Wei FC, Al Deek NF, Lin YT, Hsu CC, Lin CH. Metacarpal-like hand: classification and treatment guidelines for microsurgical reconstruction with toe transplantation. Plast Reconstr Surg. 2017;141(1):128-35.**
2. Ventola CL. Medical applications for 3D printing: current and projected uses. P T. 2014;39(10):704-11.
3. **3. Zuniga JM, Carson AM, Peck JM, Kalina T, Srivastava RM, Peck K. The development of a low-cost three-dimensional printed shoulder, arm, and hand prostheses for children. Prosthet Orthot Int. 2017;41(2):205-9.**
4. He Y, Xue GH, Fu JZ. Fabrication of low cost soft tissue prostheses with the desktop 3D printer. Sci Rep. 2014;4(6973):1-7.
5. Cai H. Application of 3D printing in orthopedics: status quo and opportunities in China. Ann Transl Med. 2015;3(Suppl 1):S12.
6. **Tan XP, Tan YJ, Chow CSL, Tor SB, Yeong WY. Metallic powder-bed based 3D printing of cellular scaffolds for orthopaedic implants: a state-of-the-art review on manufacturing, topological design, mechanical properties and biocompatibility. Mater Sci Eng C Mater Biol Appl. 2017;76:1328-43.**
7. Liu F, Shi D, Lu SZ. [Classification of hand and its significance]. Zhonghua Wai Ke Za Zhi. 1994;32(2):73-6.

8. Tan H, Yang K, Wei P, Zhang G, Dimitriou D, Xu L, et al. A novel preoperative planning technique using a combination of CT angiography and three-dimensional printing for complex toe-to-hand reconstruction. J Reconstr Microsurg. 2015;31(5):369-77.
9. **Adani R, Woo SH. Microsurgical thumb repair and reconstruction. J Hand Surg Eur Vol. 2017;42(8):771-88.**
10. Morrison WA, O'Brien BM, MacLeod AM. Experience with thumb reconstruction. J Hand Surg Br. 1984;9(3):223-33.
11. Waitzenegger T, Lantieri L, Le Viet D. [Dislocation of the thumb extensor tendons: an anatomical, clinical study and new classification]. Chir Main. 2014;33(4):291-4.
12. Pierer G, Steffen J, Hoflehner H. The vascular blood supply of the second metacarpal bone: anatomic basis for a new vascularized bone graft in hand surgery. An anatomical study in cadavers. Surg Radiol Anat. 1992;14(2):103-12.
13. Poole JL. Measures of hand function: Arthritis Hand Function Test (AHFT), Australian Canadian Osteoarthritis Hand Index (AUSCAN), Cochin Hand Function Scale, Functional Index for Hand Osteoarthritis (FIHOA), Grip Ability Test (GAT), Jebsen Hand Function Test (JHFT), and Michigan Hand Outcomes Questionnaire (MHQ). Arthritis Care Res (Hoboken). 2011;63(Suppl 11):S189-99.
14. Pet MA, Ko JH, Vedder NB. Reconstruction of the traumatized thumb. Plast Reconstr Surg. 2014;134(6):1235-45.
15. Morrison WA, O'Brien BM, MacLeod AM. Thumb reconstruction with a free neurovascular wrap-around flap from the big toe. J Hand Surg Am. 1980;5(6):575-83.
16. **Zang CW, Zhang JL, Meng ZZ, Liu LF, Zhang WZ, Chen YX, Cong R. 3D Printing technology in planning thumb reconstructions with second toe transplant. Orthop Surg. 2017;9(2):215-20.**
17. **Li F, Liu C, Song X, Huan Y, Gao S, Jiang Z. Production of accurate skeletal models of domestic animals using three-dimensional scanning and printing technology. Anat Sci Educ. 2018;11(1):73-80.**
18. Scolozzi P, Jaques B. Computer-aided volume measurement of posttraumatic orbits reconstructed with AO titanium mesh plates: accuracy and reliability. Ophthalmic Plast Reconstr Surg. 2008;24(5):383-9.
19. Herlin C, Koppe M, Beziat JL, Gleizal A. Rapid prototyping in craniofacial surgery: using a positioning guide after zygomatic osteotomy: a case report. J Craniomaxillofac Surg. 2011;39(5):376-9.
20. Watson RA. A low-cost surgical application of additive fabrication. J Surg Educ. 2014;71(1):14-7.
21. Bagaria V, Deshpande S, Rasalkar DD, Kuthe A, Paunipagar BK. Use of rapid prototyping and three-dimensional reconstruction modeling in the management of complex fractures. Eur J Radiol. 2011;80(3):814-20.
22. **Coles-Black J, Chao I, Chuen J. Three-dimensional printing in medicine. Med J Aust. 2017;207(3):102-3.**

DOI: http://dx.doi.org/10.1590/1413-785220212904238960

INTERPOSITION-ARTHROPLASTY OF THE ELBOW: SYSTEMATIC REVIEW

ARTROPLASTIA DE INTERPOSIÇÃO EM COTOVELO: REVISÃO SISTEMÁTICA

THIAGO BERNARDO CARVALHO DE ALMEIDA[1], EDMILSON DA SILVA REIS[1], LUCIANO PASCARELLI[1], ROBERTO RANGEL BONGIOVANNI[1], RENATO LOUREIRO TEODORO[1]

1. Rede D'Or São Luiz, Hospital IFOR, Grupo de Ombro e Cotovelo, São Bernardo do Campo, SP, Brazil.

ABSTRACT

Objective: To perform a systematic review of the main methods and indications of interposition arthroplasty in the rigid elbow. Methods: The research was carried out by three independent researchers, in the databases PubMed, Medline and Embase, according to the descriptors selected as a research strategy and filters selected in the inclusion criteria. Results: In total, 21 studies were found with the afore mentioned descriptors and which were considered adequate according to the design and relevance according to the type of study and inclusion filters. There was a very strong correlation between the searches of the three researchers (k = 0.809). At the end, 14 complete studies were presented, all of which were included. Conclusion: The main finding of this study was to note that there is an evident lack of research with a high level of real effectiveness and indication for interposition arthroplasty in the rigid elbow. Most studies point to positive results when the patient is young and a total arthroplasty is not indicated. No meta-analysis or randomized clinical trial was found for this specific topic, despite being a technique applied in clinical practice for some decades and showing good results. ***Level of Evidence V, Systematic Review.***

Keywords: Arthroplasty. Elbow. Treatment Outcome.

RESUMO

Objetivo: Realizar uma revisão sistemática dos principais métodos e indicações da artroplastia de interposição em cotovelo rígido. Métodos: Pesquisa realizada por três pesquisadores independentes nas bases de dados PubMed, Medline e Embase, segundo os descritores selecionados como estratégia de busca e filtros estabelecidos nos critérios de inclusão. Resultados: Foram encontrados 21 estudos com os descritores selecionados, que foram avaliados conforme seu desenho e relevância segundo os filtros do tipo de estudo e critérios de inclusão. Houve correlação muito forte entre as buscas dos três pesquisadores (k = 0,809). Ao final, restaram 14 estudos completos, e todos foram incluídos. Conclusão: Observou-se que existe uma carência evidente de pesquisas com nível de confiabilidade alto para a real eficácia e indicação da artroplastia de interposição no cotovelo rígido. A maioria dos trabalhos aponta para resultados positivos quando o paciente é jovem e a artroplastia total não é indicada. Não foi encontrada nenhuma metanálise ou ensaio clínico randomizado para esse tema específico, apesar de ser uma técnica aplicada na prática clínica há algumas décadas e que apresenta bons resultados. ***Nível de Evidência V, Revisão Sistemática.***

Descritores: *Artroplastia. Cotovelo. Resultado do Tratamento.*

Citation: Almeida TBC, Reis ES, Pascarelli L, Bongiovanni RR, Teodoro RL. Interposition-arthroplasty of the elbow: systematic review. Acta Ortop Bras. [online]. 2021;29(4):219-222. Available from URL: http://www.scielo.br/aob.

INTRODUÇÃO

The sequelae of severe elbow fractures, arthritis and infections, contribute to varying degrees of stiffness in this joint, and this involvement is commonly called stiff elbow.[1-3] In the literature, it is described that performing most activities with the upper limbs depends on an elbow range of motion of 100° (Morrey's functional range), ranging between 30 and 130°, and of 100° of pronation-supination. Loss of these degrees of movement generates functional deficits, preventing simple activities of daily living, such as taking the hand to the mouth and personal hygiene, among others, in addition to progressive and disabling pain.[4,5] Fractures are largely responsible for this sequel, mostly in young people who practice activities involving great movement of this joint. Elbow arthritis is a debilitating condition that presents with pain, stiffness, and loss of function. The etiology varies and both osteoarthritis and inflammatory arthritis affect the elbow. Primary elbow osteoarthritis is rare and most cases are the result of post-traumatic changes.[6-8] Rheumatoid arthritis is the most common inflammatory arthritis affecting the elbow. Surgery is indicated when conservative treatment fails. In older, low-demand patients, total elbow replacement provides acceptable first-line therapy. However, the young, high-demand patient

All authors declare no potential conflict of interest related to this article.

The study was conducted at IFOR Hospital Rede D´Or São Luiz
Correspondence: Thiago Bernardo Carvalho de Almeida. Rua Marcel Preotesco 134, apto 123, torre B, São Bernardo do Campo, SP, Brazil, 09750225. dr.tbca@hotmail.com

Article received on 06/01/2020, approved on 08/27/2020.

poses a challenge because total elbow replacement is not a long-term solution for this group as a result of high rates of relaxation.[9-11]
Surgical treatment for elbow arthritis includes arthroscopic debridement, ulnohumeral arthroplasty, interposition arthroplasty, resection arthroplasty, total elbow arthroplasty, and arthrodesis. The main goal of treatment is to reduce pain and improve function without compromising future surgical options. Arthroplasty is performed for mild to moderate degeneration and can be performed arthroscopically or openly. Satisfactory pain and stiffness relief is achieved in up to 75% of patients, although these results typically deteriorate during the first decade.[5] Although total elbow arthroplasty is used in patients with osteoarthritis,[6] the consensus seems to be that the result is less favorable in younger and more demanding patients. Arthroplasty and resection arthrodesis are not attractive options as a result of a loss of function, and many feel that these procedures should only be used as a last resort.
In this sense, despite being one of the oldest treatment options for elbow arthritis, interposition arthroplasty (IA) seems to be an intermediate solution in this matter. Over the years, various types of interposition have been used, ranging from synthetic grafts to the current preferred option of the Achilles tendon allograft[8-10] with or without a hinged external fixator as an adjunct[11] It is considered a salvation option in patients where conservative treatment has failed and total elbow arthroplasty is relatively contraindicated[9] Due to its importance, this study aimed to carry out a systematic review of the main methods and indications of interposition arthroplasty in stiff elbow.

MATERIALS AND METHODS

Research strategy

Two reviewers independently performed a search with the same descriptors and in the *PubMed, Medline and Embase* databases, for studies published until December 5, 2017. The following descriptors were used: *"Interposition arthroplasty", "Stiff elbow", "Functional results"*. The following filters were used to reach the expected final result: *"Randomized Controlled Trial; "Clinical Trial" "Meta-Analysis" "Systematic Reviews"; "Case Reports".*

Eligibility and Selection Criteria

The studies found were subjected to the following inclusion criteria:
- Studies related to the topic;
- Studies published in indexed journals;
- Articles in languages: English, Spanish and Portuguese;
- Studies conducted on humans;
- Articles available in full version.

The exclusion criteria were:
- Case report studies with incomplete description of the type of graft and follow-up time.

Investigated variables and extracted data

Two independent investigators took part in the search, which followed the same criteria in the selected studies, collecting the following data: Study design, Type of graft, Follow-up time and Study outcome.

RESULTS

Identification of studies and characteristics

According to the search strategy, 21 studies were found with the aforementioned descriptors, which were evaluated for their content according to the study type filters and inclusion criteria. There was a very strong correlation between the searches of the three researchers (k = 0.809). In the end, 14 complete studies remained, all of which were included (Table 1).[2-15]

Table 1. Studies used

Study	Study design	Age group	Follow-up time	Clinical outcome
Burkhart et al.[2]	Review	Young adult	Not described	Interposition arthroplasty preserves the revision options of reinterposition arthroplasty, as well as the withdrawal of total elbow arthroplasty
Chauhan et al.[3]	Case series	Average age 57 years old	Average follow-up:3.6 years	An arthroscopically assisted elbow interposition arthroplasty without external hinged fixation can provide satisfactory mid-term results as a rescue procedure for a difficult condition with limited options
Ersen et al.[15]	Case series	31 years average	87 months	Interposition arthroplasty is a rescue procedure that appears to have good long-term functional results, especially in patients for whom elbow arthroplasty is not suitable. The use of an Achilles allograft for interposition can protect the joint space in the long term.
Sears et al.[4]	Review	Young and active population	1 year	Patients who report stiffness and pain at the end of movement may benefit from arthroscopic or open osteocapsular debridement. Those with advanced degenerative changes and pain across the range of motion may require joint restoration with interposition arthroplasty
Kokkalis et al.[5]	Review	Young adults	Not Reported	Arthroscopic or open synovectomy, debridement arthroplasty, and interposition arthroplasty are generally recommended for the young, active patient population.
Miyazaki et al.[6]	Case series	Average 38 years	54 months	Interposition arthroplasty with fascia lata associated with the use of a dynamic external fixator in stiff elbow is a viable alternative for patients who do not have an indication for total elbow arthroplasty
Nolla et al.[7]	Case series	Not described	7 years	They obtained good results in elbow extension
Cheung et al.[8]	Review	Young population	Not described	In young patients with primary osteoarthritis, interposition arthroplasty is a valid option, although arthroscopic debridement has been presented as one of the main advances in these cases today.
Larson and Morrey[9]	Case series	Young patients	Not described	They observed that the most suitable for interposition arthroplasty were those patients who had post-traumatic elbow arthrosis
Neidel[10]	Case report	10 years	77 years	Interposition arthroplasty in multifractures of the elbow was a technique chosen due to the patient□s age and presented definitive and positive results.
Mansat[11]	Review	Not described specific age group	Not Reported	In the surgical treatment of rheumatoid elbow, interposition arthroplasty is a valid option before total arthroplasty, especially in young and severely affected patients
Lee[12]	Report of 3 cases	Young patients	7.6 years	An increased mean range of motion of 65 degrees was achieved in flexion and extension in two patients and a more functional range in the third. Although this is seen as a rescue procedure in patients who are thought to be too young for elbow arthroplasty, none of the three patients experienced significant pain and none required total elbow arthroplasty after a mean follow-up of 7.6 years
Ljung et al.[13]	Case series	Young patients	Not described	The authors suggested total elbow arthroplasty as the initial treatment for rheumatoid arthritis
Morrey[14]	Case series	Not described	94 months	The results of interposition arthroplasty can be gratifying, but the technique is demanding and the complication rate is high.

As a general feature, a total of 72 patients were included in this review, with a mean age of 36.23 ± 15.14 years. Heterogeneity was observed in relation to the study design (Figure 1) and the type of graft used, most of which was derived from Achilles or fascia lata.

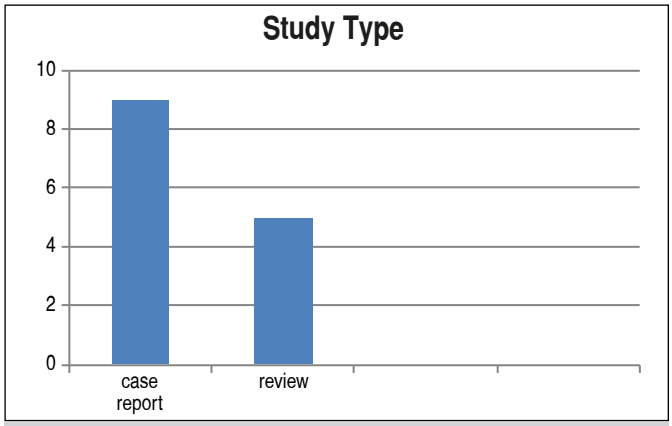

Figure 1. Number of articles according to study design.

Furthermore, the result was described as positive in 90% of the articles (Figure 2).

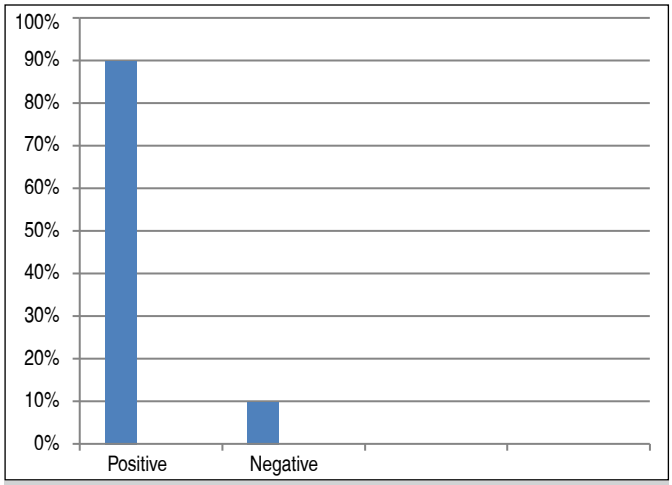

Figure 2. Percentage of articles reporting positive and negative results with the interposition arthroplasty technique.

DISCUSSION

The main finding of this study was to observe that there is an evident lack of research with a high level of reliability for the real efficacy and indication of interposition arthroplasty in stiff elbow. No meta-analysis or randomized clinical trial was found for this specific topic, despite being a technique applied in clinical practice for some decades and with good results.

Elbow arthroplasty is considered the first choice in the treatment of painful elbow arthrosis due to intrinsic factors. However, arthroplasty is not preferred in active young people, especially those who use the elbow in heavy activity. Interposition arthroplasty is one of the preferred treatment options in these patients.[1]

Several types of allografts are described in the literature, from the Achilles tendon to the fascia lata.[2,3,15] However, the long-term viability in terms of functional and imaging remains poorly explored. There is uncertainty about the indications and this treatment is rarely applied.

Interposition arthroplasty may be preferred as a salvation procedure for young patients who cannot accept the functional limitations of elbow arthroplasty.[4] It is expected that the graft will adapt and the space will disappear over time. Therefore, the goal of this treatment is to gain time with a functional elbow in patients for whom elbow arthroplasty is not suitable.

Cheung et al.[8] reported 62% of perfect and good results in 13 patients after distraction interposition arthroplasty with a mean follow-up of 63 months. Four patients required total elbow arthroplasty within 30 months.

Nolla et al.[7] reported 13 patients with a mean follow-up of 4 years and found that the flexion-extension range increased from 48° to 110° and 8 patients (62%) had good results. The largest case series on distraction interposition arthroplasty was reported by Larson and Morrey[9] who followed 38 of 69 patients who underwent distraction interposition arthroplasty for 6 years. The authors reported a significant increase in range of motion and functional score. However, 11 (29%) of 38 patients had less satisfactory results and this was associated with greater preoperative stability.

In a study by Erşen et al.,[15] 5 patients were followed for 87.6 months, with 4 patients with good results and 1 patient with satisfactory results. None of the patients had poor results despite the long follow-up. Besides, none of the patients required total elbow arthroplasty surgery.

Ljung et al.[13] only included patients with rheumatoid arthritis in their study and reported that bone destruction due to rheumatoid arthritis made it impossible to apply interposition arthroplasty in these patients. The authors suggested total elbow arthroplasty as the initial treatment for rheumatoid arthritis.

Larson and Morrey[9] observed that the most suitable for interposition arthroplasty were those patients who had post-traumatic arthrosis of the elbow.

Several options for interposition grafts, including the dermis, dura mater, fascia lata, Achilles tendon, and lipid tissue have been reported in the literature.[2,5,7,15]

Achilles tendon and fascia lata were the most frequent grafts used in case series by Cheung et al.[8] In this study, they included 13 patients in whom only fascia lata autografts were used. In a case series of 38 patients, Larson and Morrey[9] only used Achilles tendon allografts. Although not comparing these two graft options, in previously reported studies, revision rates were 31% with fascia lata and 16% with Achilles tendon.

CONCLUSION

The main finding of this study was to observe that there is an evident lack of research with a high level of reliability for the real efficacy and indication of interposition arthroplasty in stiff elbow. A maioria dos trabalhos aponta para resultados positivos quando o paciente é jovem e a artroplastia total não é indicada. No meta-analysis or randomized clinical trial was found for this specific topic, despite being a technique applied in clinical practice for some decades and with good results.

AUTHORS' CONTRIBUTIONS: Each author contributed individually and significantly to the development of this article. TBCA: data collection and work elaboration; ESR: data collection and bibliography review; RLT: data collection and bibliography review; RRB: data collection and bibliography review; LP: data collection and guidance; RRB: data collection and bibliography review.

REFERENCES

1. Papatheodorou LK, Baratz ME, Sotereanos DG. Elbow arthritis: current concepts. J Hand Surg Am. 2013;38(3):605-13.
2. **Burkhart KJ, Hollinger B. [Post-traumatic arthritis in the young patient: treatment options before the endoprosthesis]. Orthopade. 2016;45(10):832-43.**
3. Chauhan A, Palmer BA, Baratz ME. Arthroscopically assisted elbow interposition arthroplasty without hinged external fixation: surgical technique and patient outcomes. J Shoulder Elbow Surg. 2015;24(6):947-54.
4. Sears BW, Puskas GJ, Morrey ME, Sanchez-Sotelo J, Morrey BF. Posttraumatic elbow arthritis in the young adult: evaluation and management. J Am Acad Orthop Surg. 2012;20(11):704-14.
5. Kokkalis ZT, Schmidt CC, Sotereanos DG. Elbow arthritis: current concepts. J Hand Surg Am. 2009;34(4):761-8.
6. Miyazaki AN, Fregoneze M, Santos PD, Silva LA, Gennaro N Jr, Checchia SL. Tratamento do cotovelo rígido com artroplastia de interposição associada ao fixador externo articulado. Rev Bras Ortop. 2009;44(4):336-41.
7. Nolla J, Ring D, Lozano-Calderon S, Jupiter JB. Interposition arthroplasty of the elbow with hinged external fixation for post-traumatic arthritis. J Shoulder Elbow Surg. 2008;17(3):459-64.
8. Cheung EV, Adams R, Morrey BF. Primary osteoarthritis of the elbow: current treatment options. J Am Acad Orthop Surg. 2008;16(2):77-87.
9. Larson AN, Morrey BF. Interposition arthroplasty with an Achilles tendon allograft as a salvage procedure for the elbow. J Bone Joint Surg Am. 2008;90(12):2714-23.
10. Neidel J. [Interposition-arthroplasty of the elbow in a child as delayed treatment of an unreduced multifragmentary fracture of the distal humerus: result after 77 years: case report and review of the literature]. Z Orthop Ihre Grenzgeb. 2002;140(3):355-7.
11. Mansat P. Surgical treatment of the rheumatoid elbow. Joint Bone Spine. 2001;68(3):198-210.
12. Lee DH. Posttraumatic elbow arthritis and arthroplasty. Orthop Clin North Am. 1999;30(1):141-62.
13. Ljung P, Jonsson K, Larsson K, Rydholm U. Interposition arthroplasty of the elbow with rheumatoid arthritis. J Shoulder Elbow Surg. 1996;5(2):81-5.
14. Morrey BF. Post-traumatic contracture of the elbow. Operative treatment, including distraction arthroplasty. J Bone Joint Surg Am. 1990;72(4):601-18.
15. Ersen A, Demirhan M, Atalar AC, Salduz A, Tunali O. Stiff elbow: distraction interposition arthroplasty with an Achilles tendon allograft: long-term radiological and functional results. Acta Orthop Traumatol Turc. 2014;48(5):558-62

DOI: http://dx.doi.org/10.1590/1413-785220212904245927

THREE-DIMENSIONAL PRINTING IN ORTHOPEDICS: WHERE WE STAND AND WHERE WE ARE HEADING

IMPRESSÃO 3D NA ORTOPEDIA: ONDE ESTAMOS E AONDE PODEMOS CHEGAR

LEANDRO EJNISMAN[1,2], CAMILO PARTEZANI HELITO[3,4], ANDRÉ FERRARI DE FRANÇA CAMARGO[1,4,5], BRUNO ARAGÃO ROCHA[4,6,7], ANDRÉ MATHIAS BAPTISTA[1], OLAVO PIRES DE CAMARGO[1]

1. Hospital das Clínicas da Faculdade de Medicina da Universidade de São Paulo, Institute of Orthopedics and Traumatology, São Paulo, SP, Brazil.
2. Hospital Israelita Albert Einstein, São Paulo, SP, Brazil.
3. Hospital das Clínicas da Faculdade de Medicina da Universidade de São Paulo, Institute of Orthopedics and Traumatology, Knee Group, São Paulo, SP, Brazil.
4. Hospital Sírio Libanês, São Paulo, SP, Brazil.
5. Hospital Santa Paula, São Paulo, SP, Brazil.
6. Hospital das Clínicas da Faculdade de Medicina da Universidade de São Paulo, Institute of Radiology, São Paulo, SP, Brazil.
7. Grupo Fleury, São Paulo, SP, Brazil.

ABSTRACT

Three-dimensional printing is a technology in expansion in the medical field. It also presents many applications in orthopedics. Our review article aims to describe 3D printing, types of 3D printers, and its use in the orthopedic field. 3D models can be created using tomography scans. Those models can then be manipulated, even simulating surgeries. It is possible to print biomodels, which will help us understand deformities and plan surgeries. Orthopedic surgeons must be updated in these disruptive technologies that may help their daily practice. ***Level of Evidence V, Expert opinion.***

Keywords: Orthopedics. Printing, Three-Dimensional. Models, Anatomic.

RESUMO

A impressão 3D é uma tecnologia em expansão na medicina, possuindo diversas utilidades na ortopedia. O objetivo deste artigo de revisão é descrever o que é a impressão 3D, seus tipos e suas aplicações na ortopedia. Modelos em 3 dimensões podem ser criados a partir da tomografia computadorizada. Estes modelos podem ser manipulados em softwares específicos, onde inclusive cirurgias podem ser simuladas. Utilizando impressoras 3D podemos criar biomodelos que nos ajudam a compreender deformidades e planejar cirurgias. É importante que o ortopedista se mantenha atualizado nestas novas tecnologias disruptivas que podem auxiliar muito no seu dia a dia. ***Nível de Evidência V, Opinião do especialista.***

Descritores: *Ortopedia. Impressão Tridimensional. Modelos Anatômicos.*

Citation: Ejnisman L, Helito CP, Camargo AFF, Rocha BA, Baptista AM, Camargo OP. Three-dimensional printing in Orthopedics: where we stand and where we are heading. Acta Ortop Bras. [online]. 2021;29(4):223-227. Available from URL: http://www.scielo.br/aob.

INTRODUCTION

Additive manufacturing, whose main representatives popularly known as 3D printing (3DP), is a class of technologies developed in the 1980s that has gained popularity only in the last decade with the cheapness of the machines and the technology involved in the process of creating 3-dimensional (3D) models. Three-dimensional printing has several applications in the most different industries such as jewelry, automotive, aviation and food.

In the area of health, 3DP has applications in Dentistry, reconstructive plastic surgery, Cardiology, among others. Since it involves bone structures and computed tomography (CT), Orthopedics is an expanding field for the use not only of 3DP, but also of all 3D technology.[1] For a better understanding of orthopedic deformities and surgical planning, often the use of 3D models in the computer (virtual environment) is enough, not requiring the impression of a physical model. Thus, the use of this technology becomes even more accessible, since most of the computer programs used for this purpose are free of charge. However, when the objective involves the treatment of complex deformities that require unconventional implants or patients with non-normal sizes, in which it is not known whether the implants available in will be suitable for treatment, the 3D printing of bone anatomy extracted from a computed tomography examination (also known as Biomodel) represents a huge performance gain.[2] Although we already have this technology available in our specialty, its use is not yet widespread on a large scale and many centers are not even aware of its existence and possible applicability. Thus, our article aims to show practical examples of current applications of 3DP and to discuss future perspectives of this technique in Orthopedics.

All authors declare no potential conflict of interest related to this article.

The study was conducted at the Institute of Orthopedics and Traumatology, Hospital das Clínicas, Universidade de São Paulo.
Correspondence: Leandro Ejnisman. Rua Dr. Ovídio Pires de Campos, 333, Cerqueira César, São Paulo, SP, Brazil, 05403010. leandro.ejnisman@gmail.com

Article received on 11/25/2020, approved on 03/16/2021.

3D Printing Method

The creation of a 3D printed bone model (Biomodel) begins with an imaging exam, usually a CT, which stores the data in DICOM (Digital Imaging and Communications in Medicine) format. Various software, both commercial, such as Mimics®, Syngo.via Siemens® and Carestream®, or free ones such as Horos®, Osirix®, 3D Slicer® and Invesalius® allow you to create a 3D file that can be printed from an image scan (Figure 1). This step in the process of selecting the region of interest within the exam is called "Image Segmentation." These programs work in a similar way. CT uses the Hounsfield scale to assign a radiodensity value to each pixel of the evaluated structure and represents it in a gray graduation when we see the exam cuts. Using tools that detect pixel intensity thresholds, the software can select the desired structure, such as a bone that stands out from the rest of the structures. Besides tools for detecting pixel thresholds, there are tools such as pixel selection by similarity, which are useful for separating one bone from another in a joint (for example, separating the tibia from the femur in one knee). Manual selection tools from the region of interest, such as in a drawing program, can also be used. By combining these tools with more complex ones, the desired structure can be limited (Figure 2) and the geometry of that region exported in a graphic file, of which the most famous is the STL ("stereolithography"). This type of graphic file represents a region in space by a mesh of triangles, so they can also be called "meshes."

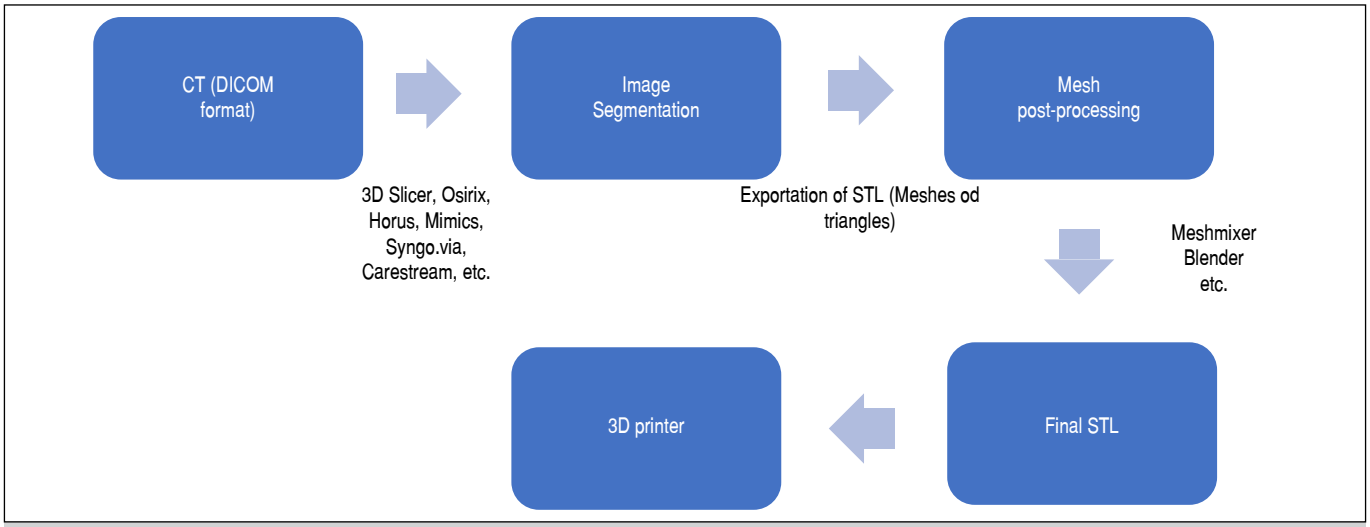

Figure 1. Schema demonstrating the steps for creating a 3D Biomodel.

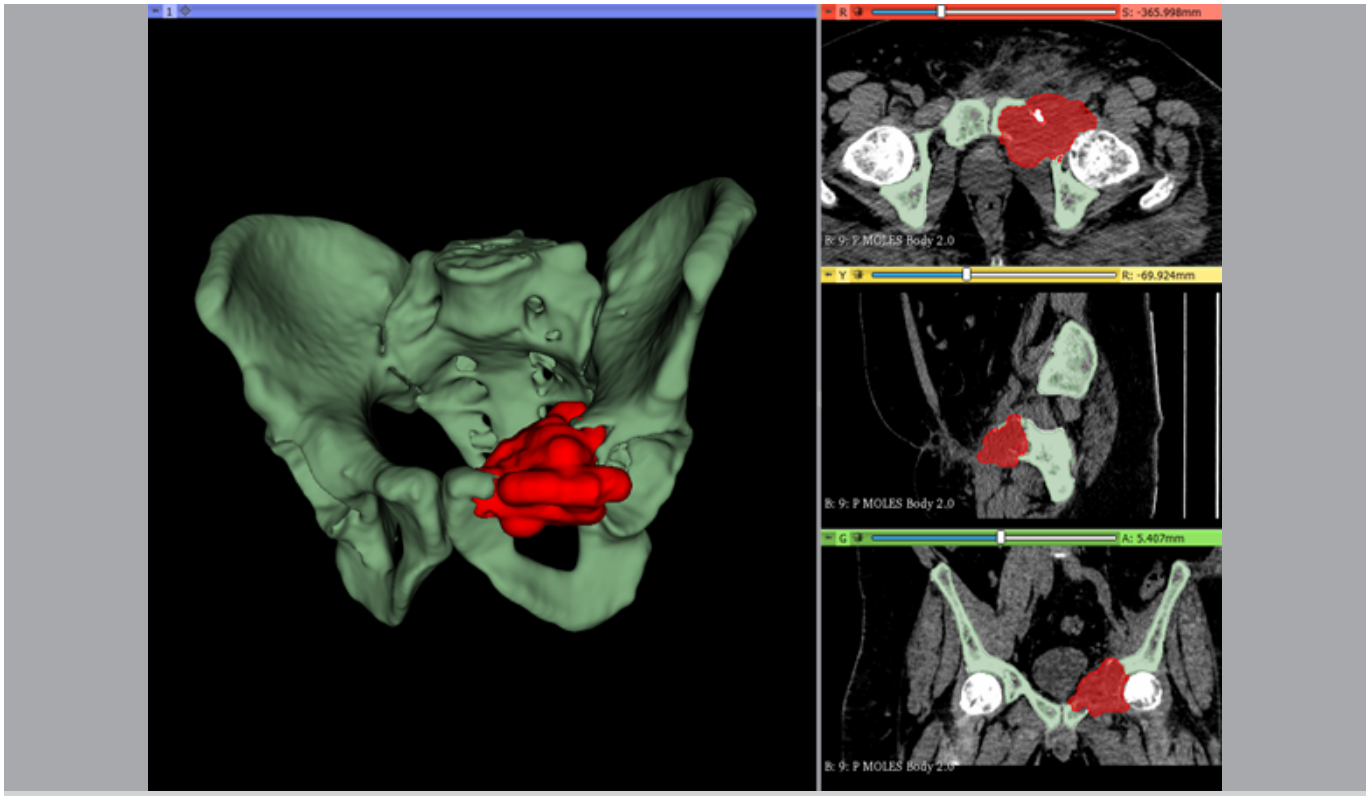

Figure 2. Example of segmentation performed in the 3D Slicer®. The patient's pelvis is selected in green, the region of interest is selected in red.

We can notice 3D reconstruction and visualization in the 3 planes (axial, sagittal and coronal).

At this time, the STL file can be directly sent to the software that controls the 3D printer; however, some other graphical manipulation software is used (several free of charge, such as Meshmixer® or Blender®), so that a post-processing is done for mesh improvements. In these programs we can erase regions that are not of interest (the ribs on a shoulder exam, for example), refine the image ("clean" artifacts), soften pixelating effect, make localized adjustments, add supports or bases, combine different STL files and even simulate corrective surgeries such as osteotomies and create custom surgical guides. After this virtual post-processing step over the generated mesh is completed, the file is again exported in STL format to be printed.

There are several types of 3D Printers, which are based on very different technologies and materials, each with advantages and disadvantages. In this article, we will mention some of the most used in orthopedic surgeries:

- FDM (fused deposition modeling) printers are the most popular printers for home use. These printers use plastic polymers that come on a roll as material in filament form. The filament is pulled by an engine to a hot extruder nozzle that melts the plastic and deposits it sequentially in layers, forming the 3D object. There are several types of materials that can be used in this type of machine in the shape of filament, such as PLA (polylactic acid), PETG (polyester type), nylon and ABS (styrene butadiene acrylonitrile). A great advantage of this type of printer are the great availability and low cost of the material, which make it a great option for printing large structures. On the other hand, its slightly coarser finish compared to other technologies and a high rate of printing failures in the cheaper models are some disadvantages.
- SLA (Stereolithography Apparatus) or DLP (digital light processing) printers print from photosensitive liquid resins. Printing occurs by a laser beam (SLA) or a light source (DLP) that is directed onto a given region, solidifying a photopolymer. The process works in layers, just like FDM. These machines that many years ago had a high cost, more recently became affordable (prices close to that of FDM) and home use. The SLA/DLP has the advantage of producing more accurate parts with greater detail. The fact that they usually have a small printing area, that the handling of resins is more complex (resins have a strong odor) and the that parts require post-processing, such as washing in isopropyl alcohol and curing, are disadvantages. In practice, we see that this type of technology has been used in the printing of surgical guides or very small parts that require great detailing.
- Electron beam melting (EBM) printers are industrial and used especially in the production of metal implants. In this process, a layer of metallic powder is subjected to a beam of electrons inside a vacuum chamber under high temperature. In each layer, the powder is deposited and the electron beam "draws" the structure in that two-dimensional cut, thus solidifying the powder only in the desired locations, layer by layer. At the end of the process, all residual powder (which has been outside the area of action of the electron beam) should be mechanically removed. This technology allows the production of orthopedic implants in titanium, with complex and customizable structures.

Orthopedic uses

Medical training

Understanding bone anatomy and disease deformities is not simple for medical students, residents, graduate students, and even our patients. Commonly, two-dimensional squeamatic drawings are used to teach orthopedics. However, anatomical structures are three-dimensional, often limiting the understanding of simplified drawings.

The possibility of printing the individual anatomy opens several opportunities for teaching.[3] Patients could better understand their deformity when holding a model of their own skeleton in their hands, and can still compare with a model of a bone without alterations. Moreover, a resident can print a bone with complex fracture to better understand the deviations, fragmentations and bone impacts, thus being able to understand and properly classify the case.

Bockhorn et al.[4] studied the application of 3DP in preoperative planning in hip preserving surgeries. CT of 16 patients with femoro-acetabular impingement were used to create 3D models. Resident physicians and patients considered that the printed model helped them to understand the deformity. Wang et al.,[5] in turn, evaluated the use of a 3D model in the teaching of total hip arthroplasty in developmental dysplasia. Surgeons were randomized to a group that used traditional the teaching technique and group that used a teaching technique with 3DP model. The use of the 3DP model presented better performance in learning according to individual questionnaires. In our country, Cocco et al.[6] showed that the use of printing helped to choose the best treatment in cases of proximal humerus fracture, being more efficient than radiography, tomography and holography.

Surgery planning

3D technology is very useful in planning surgical procedures. Based on the STL file it is possible to plan osteotomies, simulate corrections and even fixation. The orthopedist is used to planning surgeries aided by two-dimensional techniques such as transparencies and vegetable leaves for radiographs on a light panel. However, deformities and lesions are three-dimensional, which makes 3D planning more faithful to reality.

In planning, knowledge of anatomy and surgical technique is essential. Without knowledge about anatomy and the technique that will be used, the planning can be inaccurate or even unfeasible. This is one of the reasons why it is important that the orthopedist knows 3D technologies and actively participates in this process. If it is delegated to an engineer or to a physician from another specialty that does not know the surgical steps, the planning may seem appropriate on the computer, but may not be feasible due to access difficulties or the presence of soft parts that are not considered in the creation process. Patients with complex deformities or those with unconventional sizes, such as individuals with dwarfism, also benefit from preoperative planning and surgical simulation in the 3D printed model (Figure 3). In these situations, often the largest or smallest implant may not be suitable for the bone in question, making surgery with conventional implants unfeasible – without adequate preoperative planning, the surgeon could reach this conclusion only in the intraoperative period, already with the surgical route performed. In these situations, the identification of an anatomical particularity of the patient still in the planning period gives the surgeon the opportunity to develop a customized implant, specifically suitable for the case in question.

Figure 3. Example of using 3D printing for surgical planning in a patient of very short stature (1.38m). A) Anteroposterior knee radiography showing advanced osteoarthrosis of the knee; B) 3D model developed from computed tomography; C) Biomodel printed from the model of Figure 2B, in which a total knee arthroplasty was performed; D) Postoperative radiography demonstrating a result similar to the biomodel.

Another interesting possibility with 3D technology is the manufacture of surgical guides, through a 3D object manipulation software (such as the aforementioned Meshmixer® or Blender®). The patient's bone anatomical repairs (such as an iliac spine, an epicondyle, a supracondylar crest, a process, or a tuberosity) are used to create a negative on the contact surface of the guide with the bone. Thus, the guide fits perfectly into the anatomical structures used as a reference – we should not plan a guide that is positioned on a flat bone surface, or without prominence, because in this case it would not be possible to ensure the exact positioning of the guide. The guide can present holes for Kirschner wires with predetermined inclinations that can give the osteotomy plane, or even channels through which it is possible to perform osteotomy with the use of oscillating saws or chisels.

Although this type of tool is still little used in clinical practice in Brazil, its use is widespread abroad. Shen et al.[7] conducted a study on the use of preoperative 3D planning in patients with complex tibial plateau fractures. The patients (42 in total) were divided into 2 groups: conventional planning and planning using 3D printing. Surgical time, blood loss and fluoroscopy use were shorter in the group in which 3D planning was performed. Moreover, an excellent postoperative reduction was obtained in 75% of the cases of 3D planning, and in only 45% of the traditional planning, a statistically significant difference.

Custom implants

In orthopedics, we use implants already available. When performing a surgery we have access to pieces of various sizes and with some possibilities of formats. This dynamic works for the performance of most of the procedures. However, when reconstruction of unusual anatomical regions or with large deformities is required, customization of implants can be extremely useful and is often mandatory for an adequate result.

Non-usual cases occur more frequently in arthroplasty revision surgeries, in musculoskeletal diseases associated with large joint deformities, and in cases of tumor resection. In reviews, osthelysis caused by debris presents unique characteristics in each patient. To solve this difficulty, the surgeon usually uses wedges and/or grafts to fill the bone defect as in a puzzle. The 3D technology allows the digital treatment of the model created based on CT, with the virtual removal of the previous implant, displaying in a more accurate way the existing bone defect. From this 3D model without the implant, an implant suitable for the case, respecting its unique characteristics, can be manufactured.[8]

Bone tumors also have unique characteristics, and often require non-standard resections. Most of cases the cases of resections involving long bones can be reconstructed using the modular endoprostheses available on the market. With several available combinations of meta-epifisary, articular and diaphysary parts of various sizes, long bones can be reconstructed from the femoral head to the distal third of the tibia, including an articulated knee, or from the humerus head to the elbow, without the need for customization. These locations cover most of bone tumors; however, bone tumors can also affect the distal bones to the elbow (forearm, wrist and hand), distal tibia and bones of the foot, axial skeleton and pelvic and scapular girdles (Figure 4). In these sites, the three-dimensional structure is very complex and with significant variation among patients (much larger than in long bones), and the osteotomies planned for tumor resection should follow oncological guidelines to obtain safe margins – and not to allow the subsequent placement of an existing implant. In these cases, the possibility of customization of implants suitable for planned oncological resection represents a major advance in orthopedics, because until recently the surgeon's only option was simple resection without reconstruction, often leading to a patient's large functional impairment. With the use of 3D technology, the orthopedist can now create the three-dimensional model of the affected area based on the patient's CT, virtually perform resection surgery (and creation of osteotomy guides) and, with the bone defect created, can plan and develop a most appropriated implant.

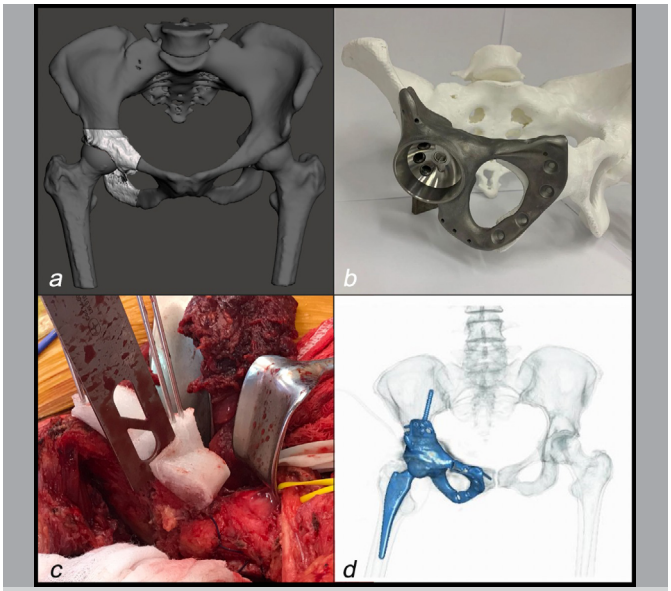

Figure 4. Stages of making a customized implant. A) Creation of a 3D model of the affected area and planning of osteotomy cuts using CAD; B) With the bone defect created virtually, the implant can be designed and a test model is printed; C) Intraoperative aspect of the guide used to perform iliac osteotomy; D) Final tomographic result.

Orthotics and prosthics

The use of 3D technology in orthotics manufacture is growing rapidly in the past decade – by definition, devices applied externally to modify the structural and functional characteristics of the neuromuscular and skeletal system. The manufacture of orthotics and prostheses is still largely manual and therefore totally dependent on the individual.[9]

The advantages of manufacturing orthotics using 3D technology (such as spinal vests, knee orthotics, wrist, ankle-foot, insoles, etc.) include lower cost, easier modifications and adaptations, and faster manufacturing (after the design phase is finished). Patients often report greater comfort with printed prosthetic shims than traditional handmade ones.[9,10]

Custom orthotics for foot and ankle have been made with 3D technology for over a decade with satisfactory effectiveness.[11] This technology was also applied for the production of customized insoles for sports shoes,[12] for plantar fasciitis or for diabetic foot.

A recent study evaluated a 3D printed immobilizer for Colles fracture;13 wrist radiographs were performed periodically to observe the palmar inclination angle, ulnar deviation angle and radio height. All these parameters were significantly better in the experimental group than in the control group (conventional splint).

CONCLUSION

Three-dimensional printing is becoming an extremely useful tool for orthopedics. In our article, we describe what is the 3DP, its types and the different uses of this disruptive technology that will be part of the routine of orthopedists.

AUTHORS' CONTRIBUTIONS: Each author contributed individually and significantly to the development of this article. LE: study conception, writing and critical review; CPH: study conception, writing and critical review; AFFC: study conception, writing and critical review; BAR: study conception, writing and critical review; AMB:study conception, writing and critical review; OPC: study conception, final approval of the manuscript.

REFERENCES

1. Ejnisman L, Gobbato B, Camargo AFF, Zancul E. Three-dimensional printing in orthopedics: from the basics to surgical applications. Curr Rev Musculoskelet Med. 2021;14(1):1-8.
2. Bagaria V, Chaudhary K. A paradigm shift in surgical planning and simulation using 3Dgraphy: Experience of first 50 surgeries done using 3D-printed biomodels. Injury. 2017;48(11):2501-8.
3. Chytas D, Johnson EO, Piagkou M, Tsakotos G, Babis GC, Nikolaou VS, et al. Three-dimensional printing in anatomy teaching: current evidence. Surg Radiol Anat. 2020;42(7):835-41.
4. Bockhorn L, Gardner SS, Dong D, Karmonik C, Elias S, Gwathmey FW, et al. Application of three-dimensional printing for pre-operative planning in hip preservation surgery. J Hip Preserv Surg. 2019;6(2):164-9.
5. Wang C, Ouyang Y, Liu H, Xu C, Xiao H, Hu Y, et al. Surgery simulation teaching based on real reconstruction aid versus traditional surgical live teaching in the acquisition of an adult total hip arthroplasty surgical technique for developmental dysplasia of the hip: a randomized comparative study. BMC Med Educ. 2020;20(1):228.
6. Cocco LF, Aihara AY, Franciozi C, Dos Reis FB, Luzo MVM. Three-dimensional models increase the interobserver agreement for the treatment of proximal humerus fractures. Patient Saf Surg. 2020;14:33.
7. Shen S, Wang P, Li X, Han X, Tan H. Pre-operative simulation using a three--dimensional printing model for surgical treatment of old and complex tibial plateau fractures. Sci Rep. 2020;10(1):6044.
8. Tserovski S, Georgieva S, Simeonov R, Bigdeli A, Röttinger H, Kinov P. Advantages and disadvantages of 3D printing for pre-operative planning of revision hip surgery. J Surg Case Rep. 2019;2019(7):rjz214.
9. Barrios-Muriel J, Romero-Sánchez F, Alonso-Sánchez FJ, Rodríguez Salgado D. Advances in Orthotic and Prosthetic Manufacturing: A Technology Review. Materials. 2020;13(2):295.
10. Herbert N, Simpson D, Spence WD, Ion W. A preliminary investigation into the development of 3-D printing of prosthetic sockets. J Rehabil Res Dev. 2005;42(2):141.
11. Wei D, Li C, Xu Y. Research progress of three-dimensional printing technique in foot and ankle surgery. Zhongguo Xiu Fu Chong Jian Wai Ke Za Zhi. 2017;31(7):880-4.
12. Salles AS, Gyi DE. An evaluation of personalised insoles developed using additive manufacturing. J Sports Sci. 2013;31(4):442-50.
13. Zeng T, Gao D-W, Wu Y-F, Chen L, Zhang H-T. Small splint external fixation combined with 3D printing brace for the treatment of Colles fractures. Zhongguo Gu Shang. 2019;32(6):513-8.

DOI: http://dx.doi.org/10.1590/1413-785220212904246573

THE MISSING LINK IN THE HISTORY OF THE LOCKED INTRAMEDULLARY NAIL

O ELO PERDIDO NA HISTÓRIA DA HASTE INTRAMEDULAR BLOQUEADA

Flávio Pires de Camargo (in memoriam)[1], Guilherme Pelosini Gaiarsa[2,3], Olavo Pires de Camargo[1], Paulo Roberto dos Reis[2], Jorge dos Santos Silva[3], Kodi Edson Kojima[3]

1. Universidade de São Paulo, Faculdade de Medicina, Departamento de Ortopedia e Traumatologia, São Paulo, SP, Brazil.
2. Hospital das Clínicas da Faculdade de Medicina da Universidade de São Paulo, Instituto de Ortopedia e Traumatologia, Grupo de Reconstrução e Alongamento Ósseo, São Paulo, SP, Brazil.
3. Hospital das Clínicas da Faculdade de Medicina da Universidade de São Paulo, Instituto de Ortopedia e Traumatologia, Grupo de Trauma, São Paulo, SP, Brazil.

ABSTRACT

Femoral Shaft intramedullary nails were first described by the Aztecs in 16th century, but the modern use of intramedullary nails as the gold standard treatment for femoral shaft fractures began with Gerald Kuntcher in 1939. From the first Kuntcher's study in 1939, to the creation of interlocking nail, a long and some minor developments were described around the world. However, a major development is missing: the first nail to have a rotational and vertical stability locking system was described by Flavio Godoy Moreira, but was never published on an indexed journal for the correct historical reference. ***Level of Evidence V, Therapeutics Studies, Expert Opinion.***

Keywords: Humans. Fractures, Spontaneous. Weight-Bearing. Fracture Fixation, Intramedullary. Femoral Fractures. Femur.

RESUMO

A história da haste intramedular bloqueada nas fraturas do fêmur se inicia com os Astecas no século 16, mas o uso moderno que a tornou o padrão ouro no tratamento destas fraturas se inicia com Gerald Kuntcher em 1939. Do estudo inicial de Kutcher até o desenvolvimento da haste bloqueada muitos pequenos desenvolvimentos foram descritos ao redor do mundo. Dentro deste desenvolvimento, a primeira haste a ter um controle vertical e rotacional foi descrito por Flavio Pires de Camargo, e nunca foi publicado em um jornal indexado que permita sua correta referência histórica. ***Nível de Evidência V, Estudos Terapêuticos, Opinião de especialista.***

Descritores: *Humanos. Fraturas Espontâneas. Suporte de Carga. Fixação Intramedular de Fraturas. Fraturas do Fêmur. Fêmur.*

Citation: Camargo FP, Gaiarsa GP, Camargo OP, Reis PR, Silva JS, Kojima KE. The missing link in the history of the locked intramedullary nail. Acta Ortop Bras [online]. 2021;29(4):228-231. Available from URL: http://www.scielo.br/aob.

INTRODUCTION

The Aztecs were the first to describe the use of intramedullary nail to fix shaft fracture, in the 16th century.[1-3] There were also some descriptions of ivory nails in the end of 19th century,[4] but the history of modern intramedullary nailing of shaft fractures begins with G. Küntscher during the World War II.[5,6]

Küntscher published the results of 39 cases in 1939 and, in 1947, another study with 107 war patients subjected to the treatment of femoral and tibia shaft fracture with intramedullary nail.[2,4,6] At the same time, roughly 60 other surgeons around the word were also working on nailing research.[1]

After the arrival of the first American soldiers with German nails back from the war, the nail use expanded in US. The unlocked Küntscher nail had a good indication in simple type fractures at the isthmus of the femur and tibia, and bad results in non-isthmus (large canal) and comminuted fractures, with shortening and bad union. To expand the indication of nailing to complex fractures attempts to create axial and rotational control with the nailing has begun.[1]

Modny and Bambara[7] in 1953, described a multiperforated nail with crossed screws to add axial and rotational control. Other authors worked in to ream the canal to insert larger nails.

In 1968, Küntscher discussed the "detensor" nail, soon called interlocking nail, with one crossing screw proximal and the other distal, to keep the length and rotation of the limb.

In the 1970s, the current design of nail with interlocking bolt was developed by a group of surgeons and spread all around the world.

This review aimed to position in the history of the intramedullary nailing the innovative idea of Professor Flavio Pires de Camargo and his own design of a nail with a distal self-locking device to improve axial and rotational stability, by analyzing a published thesis with 240 patients in 1952 (Figure 1).

All authors declare no potential conflict of interest related to this article.

The study was conducted at Instituto de Ortopedia e Traumatologia do Hospital das Clínicas Da Faculdade de Medicina da Universidade de São Paulo (SP, Brazil).
Correspondence: Guilherme Pelosini Gaiarsa. Rua Dr. Ovidio Pires de Campos 333, 3º andar, Cerqueira César, São Paulo, SP, Brazil. 05403010.guilherme.gaiarsa@gmail.com

Article received on 12/14/2020, approved on 12/17/2020.

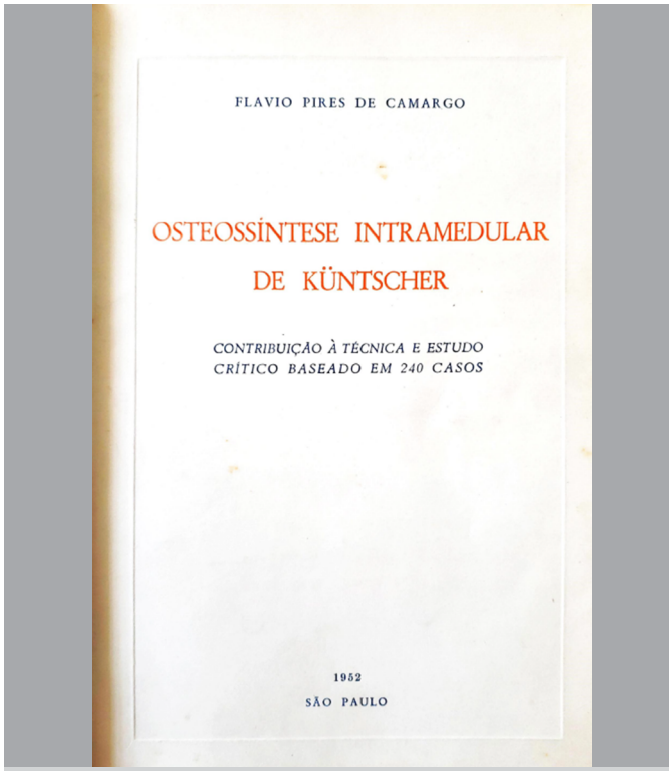

FLAVIO PIRES DE CAMARGO

OSTEOSSÍNTESE INTRAMEDULAR DE KÜNTSCHER

CONTRIBUIÇÃO À TÉCNICA E ESTUDO CRÍTICO BASEADO EM 240 CASOS

1952
SÃO PAULO

Figure 1. The thesis first page with the printed year (1952).

DISCUSSION

In Europe and North America, the number of scientific publications were increasing and intramedullary nails were a great area of development, as cited by Born.[1] And in Brazil, the Instituto de Ortopedia e Traumatologia da Faculdade de Medicina da Universidade de São Paulo was a place for technique and implant development, counting on its own workshop to produce the created implants (Figure 2).



Different nail models: 1 — Küntscher's nail; 2 — Rocher's nail; 3 — Hansen and Street's nail; 4 — Rush's nail; 5 — Westerborn's V-shaped nail; 6 — Delitala's T-shaped nail; 7— Godoy Moreira's nail; 8 — author's model for factures of 1/3 inferior of femoral diaphysis.

Figure 2. The different nails used at the time and the last one with the distal blades to improve axial and rotational control.

Even though Prof. Flavio's thesis is cited on a Küntscher's book[8] as a reference, it was never published on an indexed journal to be easily accessible for research and citation.

A very similar system was described as Brooker-Willis nail,[9-12] and one recent presentation on the EFORT congress refers to Prof. Flavio thesis pioneering system.[10]

Between August 1946 and December 1951, 240 fractures were treated with intramedullary nail in the Hospital das Clinicas da Faculdade de Medicina da Universidade de São Paulo.

On the same period, however, the number of fresh femoral fractures on the clinic was 1269, and only 127 were treated with intramedullary nails. The use of intramedullary nails on every long bone is discussed on the thesis, therefore, this review focuses on the innovation on locking femoral nails.

The very first difference between Küntscher's technique and that described in the thesis is that the nails were made in an open focus style due to the strong fear of using X-Ray during the surgery (Figure 3).

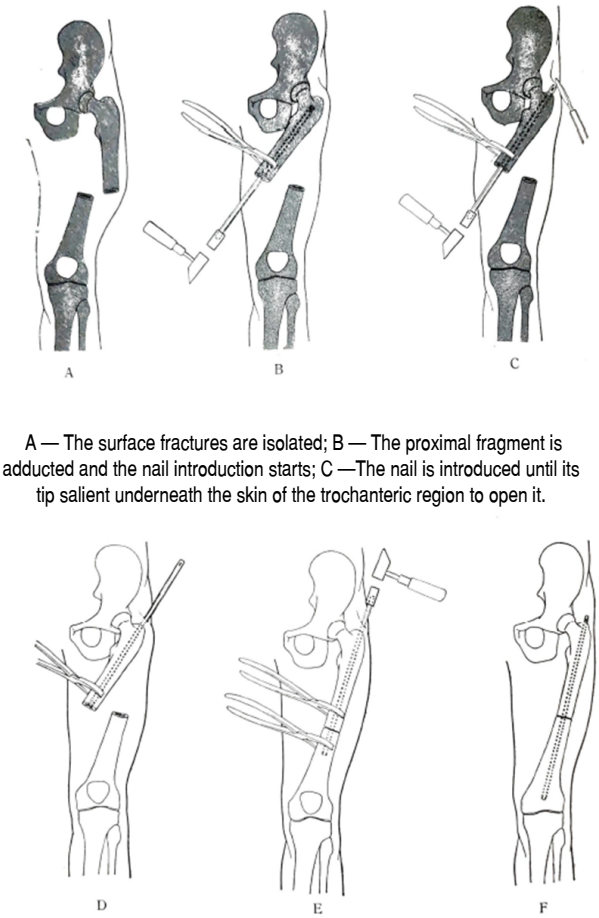

A — The surface fractures are isolated; B — The proximal fragment is adducted and the nail introduction starts; C —The nail is introduced until its tip salient underneath the skin of the trochanteric region to open it.

D — The nail introduction in the proximal fragment is completed; E — Exact reduction of the fracture and nail introduction in the distal fragment; F — Operation finished.

Figure 3. The open technique to avoid X-Ray use.

To make this technique simpler, both sides of the nail must have fit and threads compatible with the insertion device, so, for the retrograde insertion from the fracture site, the insertion device could be positioned on the other tip of the nail after the fracture reduction.

Another interesting reason to not perform the percutaneous technique is postponing surgery for some days after the trauma. The description is that the second hit to the patient could be fatal, and that waiting for some time before the surgery could be safer; however, it could cause shortening, and limiting the possibility of percutaneous reduction is probably a very early observation of this correct moment for surgery in the literature.

The real missing link is attributed by the author to the head of the department, Professor Godoy Moreira, who created a system with two blades on the tip of a metallic wire, that was inserted through the nail, and the blades opened when they found the threads on the distal part of the nail (Figure 4 and 5).



Küntscher's nail modification for the fracture of 1/3 distal femur: A — The nail in its two faces. Observe the modification on 1/3 distal. B — The stick is introduced inside of the nail. Observe in the distal end the two blades. C — With a simple mechanism the blades are opened and fixed in the spongy tissue or in the cortical internal face.

Figure 4. Schematic of the nail and the blade system.

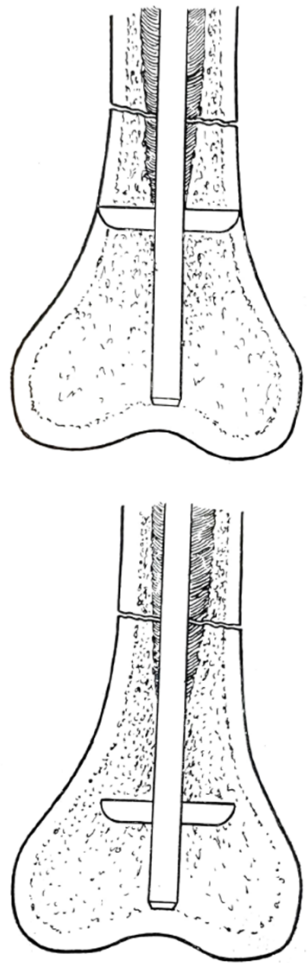

When the two blades are opened, they fix in the cortical internal face or in the osseous spongy tissue, then just low or lift the internal support. This detail must be determined before the operation.

Figure 5. Planning before the surgery to use the correct threads.

Although it was used on a small number of patients, only ten individuals at the time of the publication, good results are described, with rotational and angular control, bone healing and full weightbearing around 70 days (Figures 6 to 9).

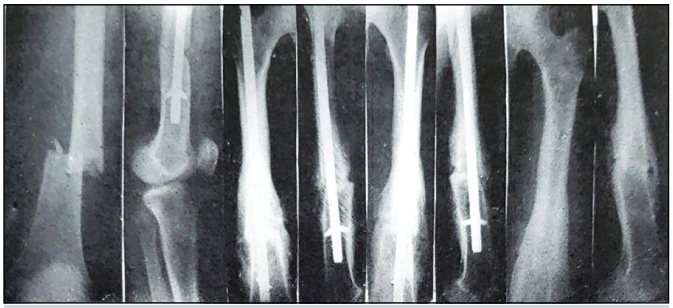

Figure 6. One of the blade cases.

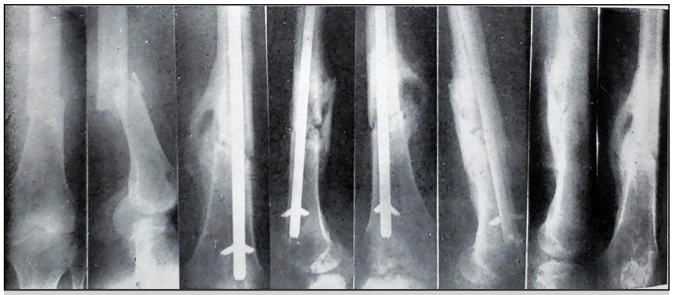

Figure 7. Fracture treated with the blade and after nail removal.

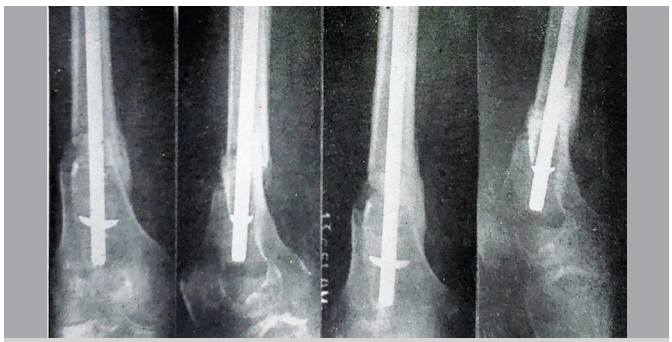

Figure 8. Another clinical example.

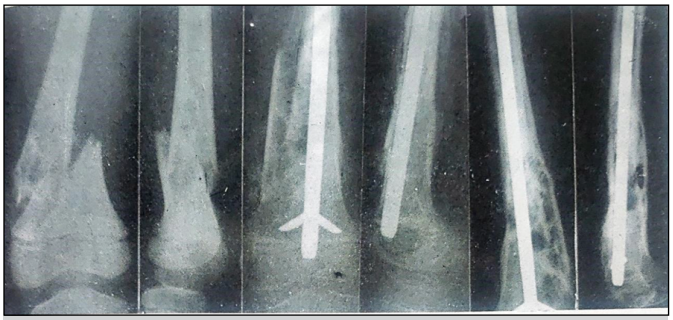

Figure 9. Pathological fracture.

The images were scanned from the original with permission, and used to bring this first description of a locking intramedullary nail back home, and pay tribute for those two pioneers of orthopedic surgery. The special Küntscher's nail was used not only on trauma, but also on some pathologic fractures to alleviate the pain and give comfort to the patients.

CONCLUSION

This thesis shows the Brazilian, and more specifically the IOT-HC-FMUSP contribution for the history of locked intramedullary nails, and this data was not accessible on an indexed paper for research and citation.

AUTHORS' CONTRIBUTIONS: Each author contributed individually and significantly to the development of this article. FPC (*in memoriam*): writing of the manuscript; GPG: manuscript and literature review; OPC: data collection, bibliography, study concept, manuscript review; PRR: manuscript review; KEK: language adaptation.

REFERENCES

1. Born CT, Pidgeon T, Taglang G. 75 Years of Contemporary Intramedullary Nailing. J Orthop Trauma. 2014;28(8 Suppl):1-2.
2. Iotov A, Novkov H, Tanchev P. Brief history of intramedullary nailing. Ortop i Travmatol. 1999;35(2):152-61.
3. Pilih IA, Čretnik A. Historical overview and biomechanical principles of intramedullary nailing. Postgrad Sch Surg Tech. 2002;(Dec):13-8.
4. Vécsei V, Hajdu S, Negrin LL. Intramedullary nailing in fracture treatment : History, science and Küntscher's revolutionary influence in Vienna, Austria. Injury. 2011;42:S1-S5.
5. Küntscher G. The intramedullary Nailing of Fractures. J Orthop Trauma. 2014;28(8 Suppl):3-10.
6. Lindvall S. Küntscher's medullary nailing. Acta Chir Scand. 1950;100(5):522-9.
7. Modny MT, Bambara J. the Perforated Cruciate Intramedullary Nail: Preliminary Report of Its Use in Geriatric Patients. J Am Geriatr Soc. 1953;1(8):579-88.
8. Küntscher G. Praxis Der Marknagelung. Stuttgart: Friedrich-Karl Schattauer; 1962.
9. Brooker Jr AF. Brook-Wills nailingof femoral shaft fractures. Tech Orthop. 1988;3(3):41-6.
10. Taneja T, Mandal D, Sood L, MahaluxmiVala J, Natali C, Achan P,et al. Interlocked nailing of the femur with the brooker–wills nail: our experience. Orthop Proc. 2009;91-B(I Suppl):37.
11. Barrick EF, Mulhern PJ. Technical dificulties with the Brooker-Wills nail in acute fractures of the femur. J Orthop Trauma. 1990;4(2):144-50.
12. Devgan A, Marya K, Kundu Z, Jain S, Siwach R, Sangwan S. Critical evaluation of management of fracture shaft femur by Brooker Willis nail. Internet J Orthop Surg. 2002;1(2):1-7.